



## A Review of Endometriosis of the Liver: An Update

Anthony Kodzo-Grey Venyo\*

Department of Urology, North Manchester General Hospital, Delaunay's Road, Crumpsall, Manchester United Kingdom

### Abstract

Endometriosis of the liver (EOL) is rare even though endometriosis is common globally. Various internet data bases were searched for the review study purpose. Less than 35 cases of EOL have been reported in pre-menopausal and post-menopausal women. EOL presents with cyclical epigastric / upper abdominal or shoulder tip pain associated with or without menstruation; a history of previous endometriosis has been reported in two thirds of patients and no previous history in a third of patients; two thirds and one third of cases have been diagnosed in the pre-menopausal and post-menopausal ages respectively. Radiological imaging would tend to show liver cysts that are non-contrast enhancing lesions that mimic other diseases which are not specific and only a third of cases have been diagnosed pre-operatively by radiological imaging/history and two thirds by histological examination of surgical specimens of the lesion. Diagnosis of EOL can be confirmed histologically by microscopic examination of liver tissue which tends to show typical endometrial tissue which is composed of glandular and stromal components and immunohistochemistry study finding of positive staining for oestrogen receptor in both the glandular and stromal elements; progesterone receptor in both the glandular and stromal component; vimentin in both the glandular and stromal components of the endometriotic lesion. Treatment involves surgical excision of the lesion or ultrasonic aspiration and medical treatment with Danazol or gonadotrophin releasing agonists but there is no consensus. EOL is rare and its diagnosis would require a high index of suspicion.

**Key Words:** Endometriosis of liver; Hepatic endometriosis; endometrial tissue; oestrogen receptor, progesterone receptor; vimentin.

\*Corresponding Author: Dr. Anthony Kodzo-Grey Venyo, MB, ChB, FRCS(Ed), FRCSI, FGCS, Urol. LLM. Department of Urology, North Manchester General Hospital, Delaunay's Road, Crumpsall, Manchester, United Kingdom. Email: [akodzogrey@yahoo.co.uk](mailto:akodzogrey@yahoo.co.uk)

Received: June 20, 2016 Accepted: September 12, 2016. Published: September 20, 2016. This is an open-access article distributed under the terms of the Creative Commons Attribution License, which permits unrestricted use, distribution, and reproduction in any medium, provided the original author and source are credited.

### Introduction

Endometriosis can occur sporadically in unusual sites. Endometriosis of the liver was first described by Finkel et al. [1] in 1986 and since then a few other cases of endometriosis of the liver have been reported. Endometriosis of the liver is still rare hence a number of clinicians may be unfamiliar with the disease. The ensuing review of the literature on

endometriosis of the liver is divided into two parts: (A) Overview and (B) Miscellaneous narrations and discussions from reported cases.

**Aim:** To review the literature on endometriosis of the liver

**Method:** Various internet data bases were searched including: Google, Google Scholar, Educus, and PUBMED. The search words that were used included: Endometriosis of liver and hepatic endometriosis.

### Result / Literature Review

#### (A) Overview

#### Definition

Endometriosis is a terminology which has been coined for presence of endometrial tissue outside the confines of the uterus that does induce a chronic inflammatory reaction [2]

## General Comments

### Epidemiology

- It has been stated that endometriosis in general tends to affect about 10% within the reproductive age group; and it also tends to affect about 2.5% of women within the post-menopausal ages; the disease furthermore affects women belonging all ethnic and social groups. [3]
- With regard to age distribution of the reported cases of endometriosis of the liver, the disease has been reported in women whose ages have ranged between 21 years and 62 years (see tables 1 and 2)

### Sites and number of cases reported

Thirty (30) cases of endometriosis involving the liver have been reported and these have on a number of occasions been reported to have involved the right lobe or the left lobe of the liver alone but also occasionally involvement of both lobes of the liver have been reported (see table 1)

It has been stated that endometriosis tends to affect:

- Pelvic organs including the ovaries, fallopian tubes, uterosacral ligaments, the Pouch of Douglas, and peritoneum. [1] [4] [5] [6]
- Other parts of the body have occasionally been reported to be affected by endometriosis including: the lungs, the omentum, gastrointestinal tract, post-operative scars, lymph nodes, umbilicus, lungs, heart, pleura, diaphragm, thoracic cage, skin, urinary bladder, ureter, kidneys, pancreas, bone, arms, legs, scars and also rarely in the males [7] [8] [9] [10] [11]. Endometriosis has been reported to have affected many parts of the body with the exception of the spleen. [4] [7] [8] Endometriosis in the male has been reported in the prostate gland, urinary bladder, testis/epididymis, lower abdominal wall and in inguinal hernia scar. [6] [12] [13] [14] [15] [16] [17] [18] [19]
- The rarity of endometriosis of the liver would be appreciated after taking into consideration the global incidence of endometriosis. It has been stated that endometriosis is a very common gynaecological disorder which tends to affect between 5% and 15% of women of reproductive age and also in between 3% and 5% of post-menopausal women. [2] It has been stated that in the United States of America the number of

women who are afflicted with endometriosis is estimated at 7 million and more than 70 women globally are afflicted by endometriosis [9]. Furthermore, it has also been stated that endometriosis is one of the foremost gynaecological of admission into hospital in industrialized countries. [21] [22]

### Pathogenesis

It has been stated that currently three postulates seem to represent the scientific thinking regarding the pathogenesis of endometriosis which include (a) the metaplasia theory (metaplasia theory) which was proposed by Meyer in 1903 [23] [24]; (b) the theory of dispersion and 'transplantation' of endometrium proposed by Halban in 1924; [24] [25] (c) the theory of induction [24] [26] which is supported by Merrill. [24]

### Presentation

Endometriosis of the liver may present with:

Intermittent cyclical epigastric or right upper quadrant abdominal pain and the symptoms would tend to be associated with menstruation. There may or may not be a history of endometriosis and plus or minus previous treatment for endometriosis.

It is possible that endometriosis of the liver may be found incidentally following routine ultrasound scan, computed tomography (CT) scan, magnetic resonance imaging (MRI) scan during investigation of a different disease even though this has so far not been reported.

A patient with endometriosis of the liver could perhaps present with a sensation of a mass in the upper part of her abdomen if the endometriosis lesion is large.

At times vomiting may be a symptom of endometriosis of the liver.

### Examination findings

The general and systematic examination findings of a patient with endometriosis of the liver may be normal but during attacks of pain there could be evidence of tenderness in the epigastric region or in the right upper quadrant of the abdomen but the findings would be non-specific.

There may be a palpable mass in the right upper quadrant of the abdomen or in the epigastric region during periods of the cyclical pain but again the findings would be non-specific.

## Laboratory investigations

### Urine

Urinalysis, urine microscopy and culture are routine tests undertaken in cases of endometriosis of the liver as part of the general assessment of the patient and if there is any evidence of urinary tract infection it is treatment prior to undertaking surgical treatment of the endometriosis to improve upon the general condition of the patient.

### Haematological Investigations

Full blood count and coagulation screen are routine investigations that are undertaken as part of the general assessment of a patient who is undergoing investigation for endometriosis of the liver. These tests would not diagnose endometriosis of the liver but coagulation screen would be required prior to undertaking biopsy a cystic liver mass and before surgery is undertaken for endometriosis of the liver. Usually the INR should be equal to or less than 1.3, before the two procedures are undertaken.

### Biochemistry investigations

Serum urea, amylase, and liver function tests are routine tests that are undertaken in the assessment of patients with upper abdominal pain and nausea as part of their routine investigation. Usually the results of the tests should be normal. Nevertheless, in cases of endometriosis of the liver and obstructive jaundice the liver function tests could be abnormal and the alkaline phosphatase level may be elevated.

## Radiological investigations

### Ultrasound scan

- Ultrasound scan of the abdomen is a routine test that is carried out in cases of suspected endometriosis of the liver or cases of epigastric / right upper abdominal pain. The ultrasound scan would tend to show a mass in the liver which could be cystic with variably thickened walls and septations but these findings are not specific to endometriosis. The findings may also mimic those of non-specific liver abscess, echinococcal cyst (hydatid cyst), cystadenoma of liver, cystadenocarcinoma of the liver, hemangioma of the liver. The ultrasound scan may also indicate whether or not the liver lesion is involving any other organ for example the diaphragm, the bile duct or peritoneum.
- Ultrasound scan guided percutaneous biopsy of a cystic liver mass in suspected cases for histological examination can be used to establish

diagnosis of endometriosis of the liver pre-operatively and this would allow the surgeon to plan the appropriate surgical treatment and in the case of a patient who is at risk to undergo surgical operation because of multiple co-morbidities then medical treatment using Danazol could be tried in the first instance.

- Ultrasound scan of abdomen can be used in the follow-up assessment of patients following treatment for endometriosis to assess whether or not there is recurrence of the endometriosis.

### Computed tomography (CT) scan

- CT scan of the abdomen is a routine test that is carried out in cases of suspected endometriosis of the liver or cases of epigastric / right upper abdominal pain. The ultrasound scan would tend to show a mass in the liver which could be cystic with variably thickened walls and septations but these findings are not specific to endometriosis. The findings may also mimic those of non-specific liver abscess, echinococcal cyst (hydatid cyst), cystadenoma of liver, cystadenocarcinoma of the liver, hemangioma of the liver. The CT scan may also indicate whether or not the liver lesion is involving any other organ for example the diaphragm, the bile duct or peritoneum.
- CT scan guided percutaneous biopsy of a cystic liver mass in suspected cases for histological examination could be used to establish diagnosis of endometriosis of the liver pre-operatively and this would allow the surgeon to plan the appropriate surgical treatment and in the case of a patient who is at risk to undergo surgical operation because of multiple co-morbidities then medical treatment using Danazol could be tried in the first instance.
- CT scan of abdomen can be used in the follow-up assessment of patients following treatment for endometriosis to assess whether or not there is recurrence of the endometriosis.

### Magnetic Resonance Imaging (MRI) Scan

- MRI scan of the abdomen is a routine test that is carried out in cases of suspected endometriosis of the liver or cases of epigastric / right upper abdominal pain. The ultrasound scan would tend to show a mass in the liver which could be cystic with variably thickened walls and septations but these findings are not specific to endometriosis. The findings may also mimic those of non-specific liver abscess, echinococcal cyst (hydatid cyst), cystadenoma of liver, cystadenocarcinoma

of the liver, hemangioma of the liver. The MRI scan may also indicate whether or not the liver lesion is involving any other organ for example the diaphragm, the bile duct or peritoneum.

- MRI scan guided percutaneous biopsy of a cystic liver mass in suspected cases for histological examination can be used to establish diagnosis of endometriosis of the liver pre-operatively and this would allow the surgeon to plan the appropriate surgical treatment and in the case of a patient who is at risk to undergo surgical operation because of multiple co-morbidities then medical treatment using Danazol could be tried in the first instance.
- MRI scan of abdomen can be used in the follow-up assessment of patients following treatment for endometriosis to assess whether or not there is recurrence of the endometriosis.

#### Treatment

##### Medical treatment

Danazol can be used as treatment for endometriosis of the liver but this would require taking the medication for a long time.

##### Surgical treatment

Surgical operations that have been successfully undertaken for endometriosis of the liver include:

- (a) Pericystectomy
- (b) Hemihepatectomy (left or right depending upon the lobe of liver involved. The advantages of surgical treatment include the fact that complete excision of the lesion tends to lead to cure and no evidence of recurrence of the lesion in the liver; however in most cases reported prior to surgical treatment pre-operative diagnosis had not been established hence the surgical excision allowed for histological examination of the specimen for confirmation of the diagnosis
- (c) Surgical treatment with complete excision of the lesion is the treatment for any malignant lesion that may be associated with the endometriosis lesion
- (d) In cases where the endometriosis has extended beyond the liver for example into the diaphragm or the pericardium then surgical excision of the lesion and the associated organ through a multi-disciplinary approach of the general surgeon and the cardiothoracic surgeon would ensure complete excision of the lesions to avoid minimise cardiopulmonary complications.

##### Macroscopic features

Gross examination of an endometriosis lesion of the liver may show a partly solid and a partly cystic mass in the liver. The liver mass may be well circumscribed and the cystic mass may contain fluid which tends to be dense-chocolate coloured. The inner surface of the lesion may be yellow/white which may be uneven and nodular.

##### Microscopic features

It has been stated that even though clinical imaging characteristics of in the pelvis can be highly suggestive of the disease, the gold standard for the diagnosis of endometriosis is pivoted upon the histological examination of appropriately sampled tissue [5] [27]

Microscopic examination of liver tissue containing endometriosis would tend to show on haematoxylin and eosin staining typical endometrial tissue which is composed of glandular and stromal components

##### Immunohistochemistry

Immunohistochemistry studies of liver tissue that has endometriosis would tend to show positive staining for:

- Oestrogen receptor in both the glandular and stromal elements
- Progesterone receptor in both the glandular and stromal component
- Vimentin in both the glandular and stromal components of the endometriotic lesion

##### Differential Diagnoses

Differential diagnoses of endometriosis based upon the clinical history of the patient include:

- (a) Gall stones / cholecystitis
- (b) Hydatid cyst
- (c) Liver abscess

Differential diagnosis of endometriosis of the liver based upon radiological imaging findings include:

- Hydatid cyst
- Liver abscess (non-specific)
- Cystadenoma
- Cystadenocarcinoma
- Cystadenosarcoma
- Liver metastatic carcinoma

##### Outcome

There are only few reported cases of EOL and so far it would appear as if complete surgical excision of the lesion has been associated with good



outcome. The use of medical treatment can also lead to improvement of symptoms and to possible prevention of symptoms however there is a possibility that some patients may have side effects from the long-term treatment.

Miscellaneous narrations and discussions from reported cases

Finkel et al. [1] reported a 21-year-old woman who presented with epigastric pain and a mass in the right upper quadrant of her abdomen. He had computed tomography (CT) scan of abdomen which showed a large parenchymal liver cyst. She underwent surgical removal of the cyst and pathological examination of the specimen showed features consistent with endometriosis of the liver. Finkel et al. [1] intimated that their reported case was the first case of endometriosis of the liver to be reported in the literature.

Khan et al. [28] two cases as follows:

#### Case 1

A 31-year-old woman, presented with a 3-months history of feeling unwell, abdominal distension, and who had abnormal liver function tests. She did have a history of severe endometriosis of the pelvis. She had previously undergone hysterectomy for a double uterus as well as bilateral oophorectomy. For a period of 3 years prior to her presentation she had been receiving hormone replacement treatment by means of oestrogen and testosterone implants every six months. She was found on examination to have ascites and she was also jaundiced. She had ultrasound scan of the abdomen which showed a mass in the right lobe of her liver and a smaller mass in the left lobe of the liver. She had percutaneous biopsy of the small mass within the left lobe of the liver and histological examination of the specimen was reported to have shown endometrial tissue. She had computed tomography scan (CT) scan which showed a huge non-enhancing mass that was lobulated within the right lobe of her liver parenchyma which had extended into the right sub-hepatic area. The CT scan also showed another mass in the left lobe of her liver. Both her ascites and jaundice worsened. She developed portal vein thrombosis which was confirmed by angiography. She underwent laparotomy and resection of a partly solid and partly cystic large mass in the right lobe of the liver that had extended into the retroperitoneum. Post operatively she developed bile leak which resolved over a period of six weeks. Eighteen months subsequently she

presented with pyrexia and she had a CT scan which revealed two low-attenuation masses with peripheral rim enhancement from which frank pus was aspirated and this resulted in resolution of the two masses as well as resulted in resolution of the pyrexia. She had remained asymptomatic over four year follow up period and had a CT scan six weeks after aspiration of the cysts which showed normal left lobe of liver.

#### Case 2

A 61-year-old lady was seen because she had right upper quadrant abdominal pain and was found to have an enlarged liver on examination. She had under laparotomy two years prior to her presentation at which a ruptured cyst was removed from the mesentery of her jejunum and at the same operation a cyst was removed from the mesentery of her descending colon. Histological examination of the two cysts that were removed had confirmed features that were adjudged to be diagnostic of low grade endometrial stromal sarcoma (ESS). She subsequently underwent hysterectomy and bilateral salpingo-oophorectomy but histological examination of the specimen had confirmed that the removed organs were free of tumour. During her recent admission for right upper quadrant abdominal pain, she had a CT scan of her abdomen which revealed a large mass occupying the whole of the right lobe of her liver for which she underwent right hepatectomy. Histological examination of the hepatectomy specimen showed a low-grade endometrial stromal sarcoma (ESS). She had been well for a period of 4 years follow-up without any evidence of recurrence of her ESS.

Khan et al. [28] stated the following:

- It has been stated that endometrial stromal sarcoma (ESS) can be found in extra-uterine sites with absence of a primary lesion of the uterus. [29]
- It has been stated that endometrial stromal tumours could develop from endometriosis or as a result of metaplasia from the surface of the peritoneum of the pelvis. [30]
- With regard to their second case, histological examination of the specimen of an the unruptured cyst of the bowel mesentery did show foci of inactive endometriosis that is seen after menopause which would support the postulate that endometriosis lesions could develop de novo in the absence of primary uterine lesions
- It has been stated that the prognosis of endometrial stromal sarcoma (ESS) is related to

the mitotic index of the resected lesion (1-10) [30]. The fact that with regard to their case the mitotic index was 1 and the patient did not have any recurrence of the disease after four years would indicate that such lesions should be treated by resection.

- They would advise that endometriosis and endometrial stromal sarcomas should be taken into consideration in women who have liver tumours of unknown aetiology and that in their opinion surgical resection such lesions would appear to play vital role in the treatment of the disease.

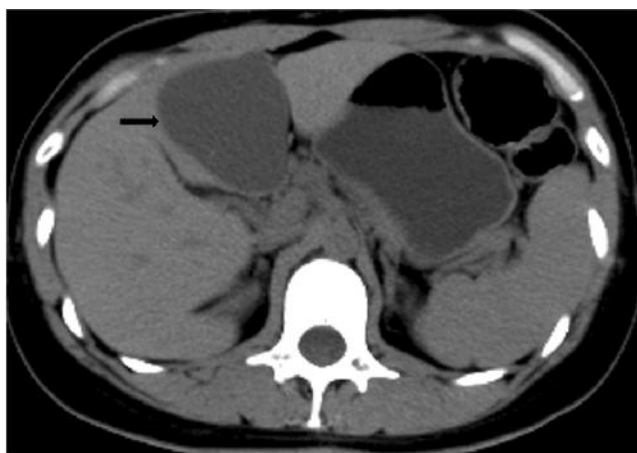
Huang et al. [31] reported a 56-year-old woman, who had previously undergone hysterectomy and bilateral salpingoophorectomy eight years preceding earlier for endometriosis that had involved both fallopian tubes, ovaries, cervix, and pouch of Douglas, who had presented with intermittent epigastric pain for a number of years without menstruation. She had had ultrasound scan of abdomen elsewhere and was found to have a large tumour mass. Her abdominal examination did not reveal any obvious abnormality. Her blood test results including full blood count, serum biochemistry tests, hepatitis B and C screen were all normal. She had radiological investigations including abdominal ultrasound scan, magnetic resonance imaging scan, and computed tomography scan which showed a well circumscribed cystic mass in the left lobe of the liver with irregular soft tissue components. She had angiography which showed a hypo-vascular mass which was submitted to fine needle aspiration that yielded dark brown fluid and a few atypical columnar cells for which a provisional diagnosis of adenocarcinoma of the liver was made. She underwent laparotomy which showed a cystic mass in segment 4 of the liver for which extended left hepatectomy was undertaken. No other abnormality was found during the operation. Macroscopic examination of the lesion showed a well circumscribed cystic mass which contained dense chocolate coloured fluid. The inner surface of the cyst was found to be yellowish/white, uneven and nodular in appearance. Microscopic examination of the lesion showed that the wall of the cyst had consisted partially of endometrial glandular and stromal elements, which was adjudged to have characterized endometriosis. Immunohistochemistry studies of the specimen showed positive staining for oestrogen receptor, progesterone receptor and vimentin respectively in both the glandular and the stromal components of the lesion. The liver tissue

that was adjacent to the lesion as well as the gall bladder, were normal. Huang et al. [31] stated the following:

- Finkel et al. [1] reported the first case of endometriosis of the liver in 1986 in a 21-year-old lady who had presented with epigastric pain, nausea and vomiting and that Finkel et al. [1] reported that her liver cyst which measured 13 cm in diameter was located in the left lobe of the liver.
- Four more cases of endometriosis of the liver had been reported after initial reported case of endometriosis of the liver at the time of the report of their case.
- With regard to the five previously reported cases and their case (a total of 6 cases), the ages of the patients between 21 years and 62 years, the cystic lesions were found either in the left lobe or right lobe of the liver, 4 of the tumours were solitary and had measured greater than 10 cm in diameter, the patients most commonly had presented with abdominal pain without any association with menstruation, 3 of the patients did have co-existent or a previous history of pelvic endometriosis, and 4 of the patients had on a previous occasion undergone pelvic

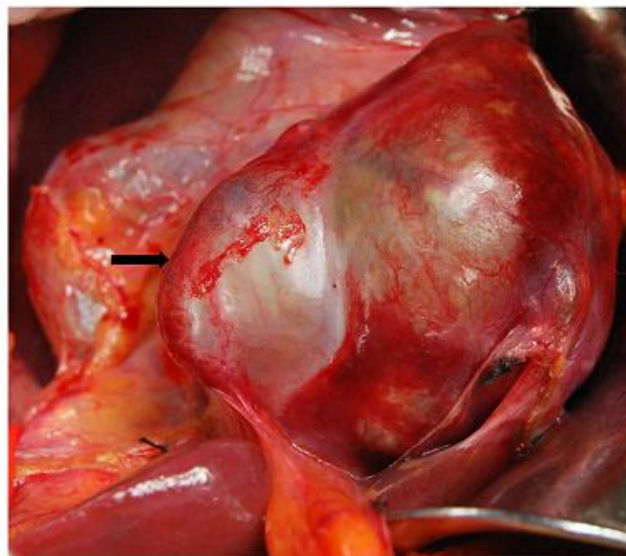
Liu et al. [5] reported a 36-year-old primigravida lady who was referred for investigations because she had presented with a 3hour history of right upper quadrant abdominal pain in the early part of 2013 for which she which she had ultrasound scan and was referred six months later in August 2013. She did not have any previous history of endometriosis. The ultrasound scan did show a 6-cm lesion, a cystic mass in segment III of the left lobe of the liver. In view of the fact that the patient had coped with her symptoms her planned laparotomy was postponed and refused further treatment. She had not been exposed to any hepatotoxic drugs, oestrogens, progestins or contraceptive pills and she had been menstruating and not in menopause. Her general and abdominal examinations were normal. Her laboratory investigations including full blood count, serum biochemistry, and her hepatitis B as well as hepatitis C antibody screens were all normal. Her tumour marker screen which included carcinoembryonic antigen (CEA), carbohydrate antigen 19-9, alpha fetoprotein (AFP), and carbohydrate antigen 125 were normal. She had CT scan of abdomen which revealed a 6.5 cm x 6.0 cm, cystic lesion which was thick walled and associated with complex septations in segment III of the left lobe of the liver (see figure 1). A provisional

diagnosis of hepatic cystadenoma, or hepatic cystadenocarcinoma was made. She underwent laparotomy in which a large cystic tumour occupying segment III of the liver was found (see figure which shows the macroscopic features of the mass) and from the wall of the cyst frozen section biopsies were taken and frozen section pathological examination of the biopsy specimen confirmed endometriosis of the liver. The endometriosis lesion was completely removed by means of pericystectomy. The rest of the contents of her abdomen were normal. She was well without any evidence of recurrence of her lesion at her 3-month follow-up. Histological examination of the specimen showed a lobulated cyst, which had adjacent normal liver parenchyma. The cyst wall consisted of partially endometrial glandular tissues and stromal components (see figure 3a) which were adjudged to be characteristic of endometriosis. Immunohistochemistry studies of the specimen did show that the stromal cell and epithelial cells had expressed strongly positive staining for oestrogen receptors and progesterone receptors (see figure 3b and 3c). Furthermore immunohistochemistry studies of the lesion also showed positive staining for CD10, CK7, and HepPar-1 which had confirmed the epithelial origin of the cyst (see figure 3d, 3e, and 3f). There was no evidence of any atypical cells and the aforementioned pathological results had confirmed the diagnosis to be that of benign endometriosis. Liu et al. [5] stated that their case was the 22<sup>nd</sup> case of endometriosis of the liver to be reported.



**Figure 1:** Hepatic CT scan showing a well circumscribed cystic lesion of 6.5 x 6.0 cm located in segment III of the left liver lobe. Reproduced from: Liu K, Zhang W, Liu S, Dong B, Liu Y. Hepatic endometriosis: a rare case and review of the literature. European Journal of Medical Research (2015) 20: 48 DOI: 10.1186/s40001-015-0137-1 with copy right © 2015 Liu et al; licensee Bio Med Central. This is An Open Access article distributed

under the terms of the Creative Commons Attribution License (<http://creativecommons.org/licenses/by/4.0>), which permits unrestricted use, distribution, and reproduction in any medium, provided the original work is properly credited. The Creative Commons Public Domain Dedication Waiver (<http://creativecommons.org/publicdomain/zero/10.1>) applies to the data made available in this article unless otherwise stated.

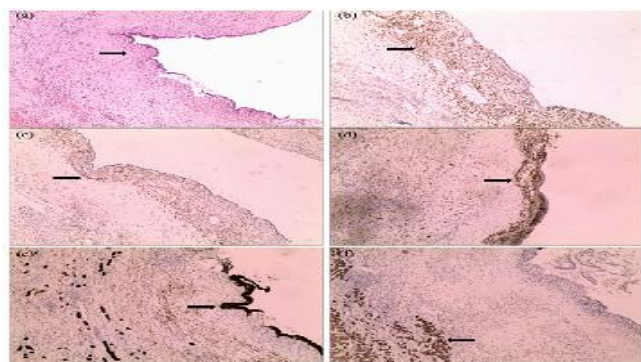


**Figure 2:** Macroscopic examination of liver mass. 6.5 x 6.0 x 5.5 cm cystic mass was presented in the left lobe of the liver with thick fibrous capsule. Reproduced from: Liu K, Zhang W, Liu S, Dong B, Liu Y. Hepatic endometriosis: a rare case and review of the literature. European Journal of Medical Research (2015) 20: 48 DOI: 10.1186/s40001-015-0137-1 with copy right © 2015 Liu et al; licensee Bio Med Central. This is An Open Access article distributed under the terms of the Creative Commons Attribution License (<http://creativecommons.org/licenses/by/4.0>), which permits unrestricted use, distribution, and reproduction in any medium, provided the original work is properly credited. The Creative Commons Public Domain Dedication Waiver (<http://creativecommons.org/publicdomain/zero/10.1>) applies to the data made available in this article unless otherwise stated.

Goldsmith et al. [7] reported a 48-year-old post-menopausal lady who was investigated for right upper quadrant abdominal pain and a cystic mass. Her liver function tests and serum tumour marker levels for alpha fetoprotein (AFP), carcinoembryonic acid (CEA), CA 19-9, and CA 125 levels were within normal range. She had undergone abdominal



hysterectomy and bilateral salpingo-oophorectomy for endometriosis of pelvis four years prior to her admission for right upper quadrant abdominal pain. She had been having hormone replacement therapy (HRT). She had ultrasound scan of abdomen which showed a 9 cm x 11 cm cystic within segment IV of her liver, the wall of which looked thick with complex septations and it had an anterior extension into the extra-peritoneal fat. Doppler ultrasound scan did show that the mass was completely avascular. She had magnetic resonance imaging (MRI) scan which demonstrated a cystic mass which measured 11 cm x 13 cm within segments IV and VIII of the liver that had bulged into segments II and III as well as it had abutted the middle and left hepatic veins (see figures 4(a) and 4(b). The MRI imaging had also shown the mass to have had high signal intensity on both T1 and T2 images which was indicative of haemorrhagic or mucinous contents and furthermore it did show incomplete septation projecting into the cyst cavity as well as irregular nodularity within the wall. The aforementioned findings were considered to be consistent with either a diagnosis of cystadenoma or cystadenocarcinoma. She underwent laparotomy and frozen section biopsies of the wall of the cyst and the septations and frozen section histological examinations. The cyst was enucleated with the use of a CUSA (Cavitron ultrasonic aspirator). Histological examination of the specimen revealed the outer wall to comprise of fibro-fatty tissue which abutted large portal tracts that had adjacent liver parenchyma with no intrinsic abnormality. Microscopic examination of the specimen also showed the inner walls of the cyst to be lined by fragments of endometrial tissue (see figure 5) and furthermore foci of endometriosis were seen in the diaphragmatic sections of the specimen (see figure 6). The patient was alive and well at her 7-years follow-up with no evidence of recurrence of her previous endometriosis.



**Figure 3:** Microscopic examination of the endometriosis cyst of the liver. Cyst and normal liver

tissue stained with hematoxylin and eosin (a) and with immunohistochemistry with estrogen receptor antibody (b), progesterone receptor antibody (c), CD10 antibody (d), CK7 antibody (e), HepPar-1 antibody (f) (x 100 magnification). No hyperplasia or atypia was observed in epithelial or stromal component. Reproduced from: Liu K, Zhang W, Liu S, Dong B, Liu Y. Hepatic endometriosis: a rare case and review of the literature. *European Journal of Medical Research* (2015) 20: 48 DOI: 10.1186/s40001-015-0137-1 with copy right © 2015 Liu et al; licensee Bio Med Central. This is An Open Access article distributed under the terms of the Creative Commons Attribution License (<http://creativecommons.org/licenses/by/4.0>), which permits unrestricted use, distribution, and reproduction in any medium, provided the original work is properly credited. The Creative Commons Public Domain Dedication Waiver (<http://creativecommons.org/publicdomain/zero/10.1>) applies to the data made available in this article unless otherwise stated.

Figure 4 (a)

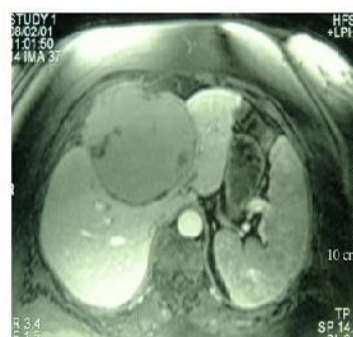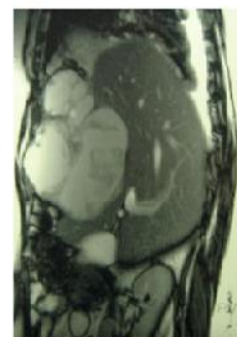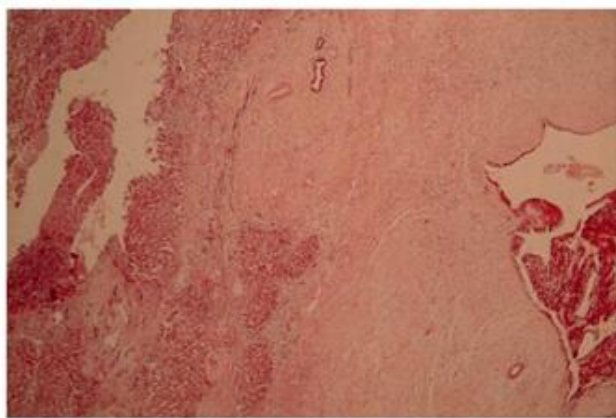


Figure 4 (b)

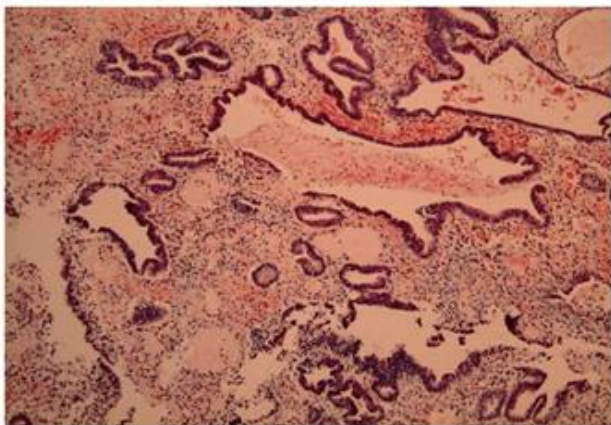


**Figure 4:** Magnetic resonance imaging (MRI) showing a cystic mass I segments IV and VIII, bulging into segments II and III and abutting the left and middle hepatic veins. The image also shows a soft tissue mass extending into the anterior abdominal wall. Reproduced from: Goldsmith P J, Ahmad N, Dasgupta D, Campbell J, Guthrie J A, Lodge J P A. Case Hepatic Endometriosis: A Continuing Diagnostic Dilemma. *HPB Surgery: a world journal of hepatic, pancreatic and biliary surgery* Volume 2009; Article ID 407206, 4 pages doi: 10.1155/2009/407206 under copyright © 2009 P. J. Goldsmith et al. This is an open access article distributed under the Creative Commons Attribution License, which permits unrestricted use, distribution, and reproduction in any medium, provided the original work is properly cited.





**Figure 5:** Low-power (X10, H + E) view of tumour capsule showing hepatocytes (on the left) and endometriotic epithelium with stroma (on the right). There are residual bile ducts entrapped within the capsule of the liver. Reproduced from: Goldsmith P J, Ahmad N, Dasgupta D, Campbell J. GuthrieJ A, Lodge J P A. Case Hepatic Endometriosis: A Continuing Diagnostic Dilemma. HPB Surgery: a world journal of hepatic, pancreatic and biliary surgery Volume 2009; Article ID 407206, 4 pages doi: 10.1155/2009/407206 under copyright © 2009 P. J. Goldsmith et al. This is an open access article distributed under the Creative Commons Attribution License, which permits unrestricted use, distribution, and reproduction in any medium, provided the original work is properly cited.



**Figure 6:** A high-power view (X25) of the endometriotic epithelium and stroma with haemosiderin laden macrophages. Reproduced from: Goldsmith P J, Ahmad N, Dasgupta D, Campbell J. GuthrieJ A, Lodge J P A. Case Hepatic Endometriosis: A Continuing Diagnostic Dilemma. HPB Surgery: a world journal of hepatic, pancreatic and biliary surgery Volume 2009; Article ID 407206, 4 pages doi: 10.1155/2009/407206 under copyright © 2009 P. J. Goldsmith et al. This is an open access article distributed under the Creative Commons

Attribution License, which permits unrestricted use, distribution, and reproduction in any medium, provided the original work is properly cited.

Asran et al. [32] reported a 61-year-old woman who was referred with a history of epigastric pain that worsened after eating but had subsided after 9 days. She had previously on three occasions undergone operations including hysterectomy 21 years earlier, right salpingo-oophorectomy 14 years earlier, and resection of a loop of bowel as a result of bowel obstruction 9 years earlier and all the operations had been undertaken because of endometriosis. She had a CT scan which did show multiple irregularly shaped, heterogeneous, low-density lesions that had been scattered throughout the liver. The lesions did show mild enhancement during the arterial phase of CT scan without any evidence of significant wash out. The CT scan also showed pelvic and mesenteric masses as well as superior mesenteric vein (SMV) thrombosis. Based upon presence of masses in the liver, pelvis and mesentery a provisional diagnosis of metastatic neuroendocrine tumour was made. Furthermore, taking into consideration presence of the irregular appearance of low attenuation areas in the liver and superior mesenteric vein thrombosis a radiological diagnosis of a sub-segmental infarction of the liver was made. CT-guided per-cutaneous biopsy of the liver mass was undertaken. Macroscopic examination of the liver biopsy specimen showed multiple, tan-brown, soft tissue that measured 1.3 cm x 0.5 cm, x 0.5 cm. Microscopic examination of the specimen showed sheets of small, round cells which had hyperchromatic nuclei and scant cytoplasm that had replaced the liver parenchyma. Microscopic examination of the specimen did not reveal any evidence of mitosis or nuclear atypia. Immunohistochemistry studies did show that the nuclei of the cells had stained positively for oestrogen receptors and progesterone receptors. Immunohistochemistry studies of the specimen also showed cytoplasmic and membranous positive staining for CD10. Based upon the microscopic and immunohistochemistry features of the biopsy specimen a diagnosis of endometrial stromal proliferation which could represent stromal endometriosis was made. Asran et al. [32] stated the following:

- Some authors [7] [33] had intimated that the radiological imaging characteristics of endometriosis of the liver tends to vary and tends to depend upon the extent, age, as well as the

degree of response to the normal hormonal fluctuations of the menstrual cycle.

- They had reviewed previously reported cases of endometriosis of the liver and had concluded that there are no ultrasound scan (US), magnetic resonance imaging (MRI) scan, and computed tomography (CT) scan features that are exclusively specific for the diagnosis of endometriosis; nevertheless, the commonest imaging characteristics of endometriosis of the liver in the reviewed reported cases are well-defined lobulated cystic lesions with solid components and septations.

Theodosopoulos et al. [34] reported a 38-year-old woman who had a 5-year history of endometriosis who had been experiencing right shoulder pain associated with menstruation. She had computed tomography (CT) scan which did show a mass in her liver. She next had magnetic resonance imaging (MRI) scan which showed a 4.4 cm x 3.8 cm mass in segments 7 and 8 of her liver which had infiltrated her right diaphragm. She underwent laparotomy which showed a tumour within the diaphragmatic part of her liver that had infiltrated the diaphragm. The mass was surgically excised by means of a wedge excision with clear margins together with the right diaphragm. Microscopic examination of the tumour showed a mixed cystic and solid mass which had endometrial type epithelium. Immunohistochemistry studies of the excised lesion showed positive staining for oestrogen receptors, progesterone receptors, and with cholangian differentiation in some of the areas. The pathological examination also revealed that the excised diaphragm had been infiltrated by endometrial tissue and the liver margins were not associated with any pathology. The patient was well at her 6-months follow-up without any evidence of recurrence of her previous endometriosis. Theodosopoulos et al. [34] stated that diagnosis of endometriosis of the liver could only be made pre-operatively by means of a high index of suspicion when the patient's symptoms are associated with menstruation.

Tuech et al. [35] reported a 42-year-old nulligravid lady who had a 22 cm x 24 cm x 30 cm cyst within the right lobe of her liver for which she underwent laparotomy and complete excision of the cyst. The laparotomy did not reveal any other lesion in her abdomen and pelvis. Histological examination of the excised cyst confirmed features consistent with the diagnosis of endometriosis. The cyst was found to be lined by fibrous tissue that contained large areas of endometrium with glands and stroma. Many glands

were cystic and were found to contain haemorrhages of different periods. Microscopic examination also showed that the encompassing liver parenchyma was widely scarred and showed deposits of hemosiderin. At her 22-month follow-up the patient was well and she had had computed tomography (CT) scan of abdomen and pelvis which did not show any evidence of recurrence of endometriosis.

Sabrina et al. [36] reported a 47-year-old woman who had developed abdominal pain and vomiting. She was diagnosed as having infectious colitis with liver abscess and was treated with antibiotics but was adjudged to have been antibiotic refractory. She had fine needle aspiration and core biopsies of her liver lesion and pathological examination of the specimens showed benign contents. At presentation the results of her blood tests were all within normal range. She underwent laparoscopic excision of a 1.4 cm cyst and pathological examination of the specimen showed endometrial glands (glands and stroma) that were arranged in an organoid fashion. Immunohistochemistry studies of the specimen showed positive staining of the glands for oestrogen receptors and positive staining for progesterone receptors. The stroma on immunohistochemistry studies showed positive staining for CD10 and smooth muscle actin (SMA). The patient who had previously had hysterectomy did not have any history or symptoms of endometriosis. Sabrina et al. [36] stated that their rare case does show the merit of taking into consideration uterus-like mass/endometriosis in the differential diagnosis of antibiotic-refractory hepatic cyst.

Hertel et al. [37] reported a 44-year-old lady who was admitted on emergency basis when she presented with severe upper abdominal pain. She had magnetic resonance imaging (MRI) scan of which the T2-weighted image had shown a large cystic mass that had a thickened wall which measured 9.5 cm x 9.1 cm x 11.2 cm within the right lobe of the liver. The MRI scan findings were interpreted as a cystic mass with differential diagnoses which included echinococcal cyst, biliary cystadenoma, and malignant neoplasm. At operation, the cystic mass was aspirated and a liquid-based cytology preparation (ThinPrep) and a cell block were made. Pathological examination of the Thin-Prep slides did show three dimensional clusters of epithelioid cells that had scant delicate cytoplasm and tissue fragments that were composed of small stromal cells which had round to oval shaped nuclei and a small amount of dense cytoplasm that had been lined by the cuboidal epithelial cells. The pathological examination also

showed occasional ciliated cells as well as abundant hemosiderin laden macrophages and examination of the cell block did show many fragments of tissue that contained glands and stroma which had associated haemorrhage and hemosiderin laden macrophages that were adjudged to be typical of endometrial tissue. Hertel et al. [37] stated that even though endometriosis of the liver is rare, it should be considered in the differential diagnosis of cystic liver masses in women especially in cases of women who have a history of endometriosis or obstetric and gynaecological surgery.

Rivkine et al. [38] reported a 51-year-old multi-parous woman who was referred to be investigated for a liver tumour. She had had a 6-months history of epigastric pain and vomiting. She had many years earlier undergone hysterectomy for uterine fibroids. She had a number of tests including liver function tests, tumour markers (CA 19.9, CEA, CA 125, alpha feto protein (AFP) which, were within normal range. She had radiological investigations including ultrasound scan, computed tomography scan, and magnetic resonance imaging (MRI) scan which had shown a lesion in the left lobe of the liver that had extended into the diaphragm and had compressed the left hepatic vein and the differential diagnoses of the lesion were thought to include: cystadenoma of the liver, cystadenocarcinoma of the liver, or cystic metastasis in the liver. She underwent laparotomy and frozen section biopsy specimen of the lesion was reported as showing endometriosis. She therefore underwent anatomical resection of the lesion which included left liver lobectomy and resection of the diaphragm. Pathological examination of the specimen did confirm presence of endometriosis only without any evidence of malignant transformation. Rivkine et al. [38] stated that the diagnosis of endometriosis in their case was established based upon pathological examination of the excised liver lesion and their case was the 15<sup>th</sup> case of endometriosis of the liver to be reported in the literature.

Kaikur et al. [39] in 2013 reported a case of a diaphragmatic endometriosis abutting the liver. Kaikur et al. [39] reported a 34-year-old woman who 5 months after she had delivered a baby, had presented with cyclical right upper quadrant upper abdominal pain which had varied in intensity and length and was more intense within the first two days of her menstruation. She was incapacitated by the pain which tended to last between 2 days and 6 days with a pain score of 8 to 9 out of 10. She had been diagnosed 6 years earlier as having endometriosis and one year prior to her admission had undergone

laparoscopy and carbon dioxide (CO<sub>2</sub>) treatment of pelvic endometriosis and at that time no abnormality was detected related to her liver or gall bladder. Based upon the cyclic nature of her pain endometriosis of the liver or diaphragm was suspected. She had magnetic resonance imaging (MRI) scan which showed diaphragmatic endometriosis. She underwent laparoscopy which revealed adhesions between the diaphragm and the anterior surface of segment V of the liver which had been caused by a mass of endometriosis. A triangular area with its base located between the leading edge of the liver above the gall bladder that measured 6 cm x 8 cm was involved by the endometriosis adhesion. A similar area of the diaphragm was involved by the endometriosis. The endometriosis adhesion was completely excised with the use of Harmonic scalpel ACE. KTP laser was utilized to photo-vaporize the residual deposits on the surfaces of the diaphragm and the liver as well as two other small endometriosis lesions found on the diaphragm. Sprayshield was applied to the raw ablated surfaces of the diaphragm and the liver to help in reducing post-operative formation of adhesions. Some surface endometriosis lesion was found lying across the left ovary and the left uterosacral ligament which was photo-vaporised and excised. Histological examination of the specimens excised from the diaphragm and the pelvis confirmed presence of endometriosis. No specimen was submitted from the surface of the liver because the lesions on the surface of the liver were treated by photo vaporization only. The patient was well at her 15-month follow-up and had been having mild aches during her menstrual periods. Even though this case report did confirm endometriosis of the diaphragm / perihepatic space and the pelvis and there was no confirmation of endometriosis of the liver per say. It would be argued that perhaps if a biopsy of the affected surface of the liver had been taken and submitted for histological examination then endometriosis involving the surface of the liver would have been confirmed and by only photo vaporizing the affected surface of the liver only the opportunity to establish liver involvement by the endometriosis lesion was lost.

Bouras et al. [40] reported a 35-year-old lady who was admitted for investigation of a cystic mass in her liver which had invaded her right ventricle and caused her pain. Her serum tumour marker levels including CA 125, CA 15-3, and CA 19-9 were raised. She underwent resection of the tumour with a small part of the right ventricle free wall, the diaphragm, and the left lobe of the liver. Histological examination of the resected specimen showed that the



mass was a benign endometrial cyst. The patient has been well post-operative and free of recurrence of endometriosis at her 5-year follow-up. Bouras et al. [40] stated that a diagnosis of endometriosis needs to be considered in cases of thoraco-abdominal cystic masses that are associated with menstruation-related pain in women of child bearing age.

Watari et al. [41] in 2012 reported a case of endometriosis of the liver in a woman who had been having periodic right upper quadrant abdominal pain. The case was reported in a Japanese journal and its details are not available to the author.

Roesch-Dieten et al. [42] reported a 25-year-old nulliparous woman who was referred with 8-months history of relapsing and remitting right upper quadrant abdominal pain. In the month preceding her admission the episodes of her symptoms had occurred more often and was reported to be related to eating fatty foods. Her menarche was at 13 years and she had regular menstrual periods associated with mild abdominal cramps. She was found on examination to be mildly tender in right upper quadrant of her abdomen. Her test results were all normal except for a low-haemoglobin of 10.9 g/dl (normal range 13 g/dl to 16.5 g/dl). She had ultrasound scan of abdomen which showed multiple small sized gall stones. Based upon a diagnosis of cholelithiasis, she underwent laparoscopic cholecystectomy and during the procedure a 6 cm x 5 cm irregular rounded haemorrhagic area was found incidentally on the surface of the liver. Furthermore, within the right parietal peritoneum small patches of haemorrhagic areas were found. Multiple biopsies were taken from the capsule of the liver and also from the haemorrhagic area of the parietal peritoneum. Histological examination of the biopsy specimens revealed presence of endometrial glands that had been surrounded by a mantle of densely packed small fusiform cells that had scanty cytoplasm and bland cytology which was adjudged to be non-neoplastic endometrial stromal cells which was confirmed by means of positive immunohistochemistry positive staining for progesterone receptors in both the glandular and stromal elements of the biopsy specimens. Histological examination of biopsies from the parietal peritoneum also revealed foci of endometriosis. The patient had been receiving danazol treatment post-operatively and has been doing well at the time of the report of the case.

Schuld et al. [43] reported a 39-year-old lady who without any history of endometriosis 7 days after she had vaginal delivery developed biliopytosis which was caused by broncho-biliary fistula. She

underwent synchronous liver resection and lung resection of a bronchobiliary fistula via laparotomy and trans-diaphragmatic approach. Histological examination of the specimen showed presence of clusters of endometrial glands embedded within the decidual stroma which were neighbouring the liver, and peri-fistulous lung tissue was shown to contain biliary pigment absorbed by macrophages and their derivatives. Schuld et al. [43] stated the following:

- Hepatic and peri-hepatic endometriosis is capable of causing a bronchobiliary fistula.
- Exacerbation of symptoms could be triggered by high oestrogen levels, physiologically dominating the last trimester
- For a rare case surgery is mandatory. For complicated bronchobiliary fistula which is caused by endometriosis, radical surgical treatment is mandatory.

Sanchez Perez, et al. [44] in 2006 reported a case of in situ adenocarcinoma which arose within a hepatic endometrioma that was treated by means of right hepatectomy. This reported case would emphasize the fact that even though majority of cases of endometriosis tend to exhibit benign biological behaviour there is a chance that endometriosis could be associated with a malignant transformation. In view of the aforementioned case, it would be advised that pathologists should carefully examine various areas of endometriosis specimens they examine to make sure there is no focus of malignant transformation in the lesion.

Nezhat et al. [45] stated that prior to 2006 all the 15 previously reported patients who had endometriosis of the liver had undergone treatment via laparotomy; however, they had managed two patients with endometriosis of the liver laparoscopically and that their two cases were the first two reported cases of endometriosis of the liver to be managed via laparoscopy. This experience reported by Nehat et al. [45] would suggest to surgeons that some cases of endometriosis of the liver can be managed by the laparoscopic approach.

Girianda et al. [46] reported a case of peri-hepatic endometriosis which would need to be differentiated from endometriosis of the liver. Radiological imaging by means of ultrasound scan, computed tomography (CT) scan, and magnetic resonance imaging (MRI) scan are means by which the nature of endometriosis lesions can be studied in order to ascertain the imaging features of the lesions and whether or not the peri-hepatic lesions are abutting or infiltrating the liver; nevertheless, it could be very difficult to ascertain confidently that a peri-

hepatic lesion has not involved part of the liver. Laparoscopy and laparotomy would appear to be the definite way to decide whether or not a peri-hepatic endometriosis has involved or has not involved the liver.

In 2003 Reid et al. [47] reported a case of endometriosis of the liver and in 2002 Jeanes et al. [48] reported a case of endometriosis of the liver associated with retro-peritoneal endometriosis which presented as obstructive jaundice and ascites. The reported case of Jeanes et al. [48] would indicate that even though endometriosis of the liver could be an isolated disease in a number of instances, in some situations endometriosis may affect more than one structure and that the mass effect of an endometriotic lesion can cause obstruction of any tubular structure in the body including the biliary tree in the reported case of Jeanes et al. [48] for which the patient presented with obstructive jaundice.

Groves et al. [49] in 2003 reported a 52-year-old woman who did not have any past history of endometriosis who underwent right hepatectomy for a lesion in the right lobe of her liver. Histopathological examination of the specimen showed endometriosis of the liver. The diagnosis of endometriosis of the liver was not established pre-operatively.

N'senda et al. [50] reported a case of a woman who had adenocarcinoma which arose in hepatic endometriosis. The lady had computed tomography (CT) scan and magnetic resonance imaging (MRI) scan which showed a huge heterogeneous mass that contained septated thick-walled cystic lesions. She underwent right hepatectomy with complete excision of the large mass. At her 2-years follow-up she was well and asymptomatic and she had a CT scan which did not show any abnormality in her liver.

Inal et al. [33] in 2000 reported a 25-year old lady with a past history of pelvic endometriosis who presented with pelvic pain and was diagnosed as having endometriosis involving the right lobe of the liver. The diagnosis of endometriosis of the liver was not established pre-operatively. She received long term treatment by means of Danazol medication with good response.

Chung et al. [51] in 1998 reported a case of endometriosis of the liver and in 1996 Cravello et al. [52] reported a 34-year-old lady who had a 2-year history of cyclic right subcostal pain. She had ultrasound scan, computed tomography (CT) scan and magnetic resonance imaging (MRI) scan of the liver which showed a 6 cm diameter mass in her liver. She received gonadotrophin releasing hormone

agonist (GnRH-a) treatment for 4 months which led to clinical improvement in her symptom as well as improvement in the radiological imaging features of the lesion. She underwent surgery to allow pregnancy that confirmed the confirmed the diagnosis of endometriosis of the liver. Cravello et al [52] intimated that endometriosis may result from metaplasia of peritoneum or from haematogenous or lymphatic spread.

Verbeke et al. [53] in 1996 reported three cases of endometriosis and two of these cases were endometriosis of the liver and the third one endometriosis of the pancreas as follows: The first case was a 34-year-old who had symptoms and signs of acute abdomen. She had magnetic resonance imaging (MRI) and computed tomography imaging (MRI) scan which was provisionally diagnosed as showing haematoma of the liver affecting the right lobe. She underwent right hemi-hepatectomy and histological examination of the specimen showed an endometrial cyst of the liver. The second reported case was that of a 62-year old lady who presented with right sided epigastric pain. She had ultrasound scan of abdomen which showed a lesion in the liver which was diagnosed as endometriosis of the liver. The third case was that of a 28-year old lady who was admitted with symptoms of recurrent epigastric pain. She had ultrasound scan of abdomen and the features of the scan was considered to have shown a post-inflammatory pseudocyst. However, she underwent distal pancreatectomy with excision of the cystic mass and histological examination of the specimen showed cystic endometriosis of the pancreas. All of the three patients reported by Verbeke et al. [53] presented with abdominal / epigastric pain and the symptoms would be considered to be non-specific. Provisional diagnosis of a cystic mass in each case was made by undertaking radiological scanning which helped with regard to definite treatment. Lessons learnt from the three cases would emphasise the need for clinicians to ensure their patients who have recurrent unexplained epigastric or abdominal pain have radiological imaging of the abdomen (ultrasound scan / CT scan / MRI scan).

In 1994 Nakanishi et al. [54] described the findings on radiological imaging diagnosis of endometriosis in the German language to draw the attention of clinicians to the imaging features that would help clinicians diagnose endometriosis of the liver.

Losa Garcia et al. [55] in 1993 reported a case of endometriosis with involvement of the urinary bladder which was associated with haemangioma of the liver. This case would illustrate

the need for clinicians to consider haemangioma and endometriosis of the liver with regard to differential diagnosis and the need to identify the radiological features as well as the histological features that differentiate the two lesions.

Grabb et al. [56] in 1986 reported a 21-year-old lady who underwent treatment by de-roofing of the cyst which had involved the left lobe of her liver. She also received danazol treatment. Rovati et al. [57] in 1990 reported a 37-year-old woman who had a history of endometriosis treatment underwent segmentectomy and danazol treatment for endometriosis which had involved the left lobe of her liver that was diagnosed pre-operatively.

Weinfeld et al. [58] in 1998 reported a 60-year-old woman with a past history of endometriosis who underwent left hepatectomy plus excision of endometriosis mass from the left lobe of her liver. Pathological examination of the specimen confirmed endometriosis of the liver.

Fluegen et al. [59] reported a 32-year-old nulligravida, and nullipara, lady who presented with constant non-cyclical right upper quadrant abdominal pain. She did not have any previous history of endometriosis. She had been diagnosed three years earlier as having had an intra-hepatic cyst in segment IV. She was closely monitored and upon evidence of progression of the cyst she underwent two laparoscopic de-roofing operations of the cyst. As a result of further progression of the cyst with evidence of obstruction of the intrahepatic biliary tree and the ensuing jaundice, she underwent multiple endoscopic retrograde cholangio pancreaticography and on three occasions trans-hepatic drains were inserted in a different hospital prior to her admission. During her admission for her right upper quadrant abdominal pain she had magnetic resonance imaging (MRI) scan which showed a 9.5 cm x 12 cm, lobulated cyst within segments IV, V, and VII (see figure 1). She had a number of serological tests and the results were all normal for (a) echinococcal disease, (b) carcinoembryonic antigen, (c) carbohydrate antigen 19.9, (d) alpha-fetoprotein, €routine laboratory work up. She underwent an ultrasonic pericystectomy with complete removal of the cyst with minimal damage to the surrounding liver. No other abnormality was found in her abdomen. Histological examination of the specimen revealed a lobulated cyst which was filled with old blood and detritus. Immunohistochemistry studies of the cyst showed strongly positive staining for oestrogen receptors and progesterone receptors, as well as for CK7 receptors and the findings were adjudged to have proven epithelial origin of the cyst. Based upon the

histological observation that there was no atypical cell detected in the specimen a diagnosis of a benign intrahepatic endometriosis was made (see figure 2). Fluengen et al. [59] stated the following:

- Out of the 18 previously reported cases of endometriosis of the liver prior to their case report, only one (5.5%) of the patients presented with cyclical right upper quadrant abdominal pain associated with menstruation. With regard to the remaining 17 patients, the patients did present with pain or tenderness, even jaundice without any obvious connection with the menstrual cycle. The absence of a typical cyclical pain does make it difficult to establish a diagnosis of extra-gonadal endometriosis.
- Out of the 18 previously reported cases of endometriosis of the liver, 12 cases (67%) had a past history of endometriosis; 6 patients (33%) did not have any history of endometriosis. Therefore the diagnosis of endometriosis should not be limited only to patients who have a known history of endometriosis.
- Out of the 18 previously reported cases of endometriosis of the liver, only 7 of the patient (39%) were diagnosed pre-operatively and in these cases trans-hepatic biopsy was undertaken and the diagnosis was established by means of histological examination.
- With regard to their patient despite a number of previous procedures undertaken in the management of their patient before referral to their hospital no samples of specimens were obtained and sent for histological examination which in their opinion delayed the diagnosis and perhaps prolonged the patient's symptoms therefore they would recommend biopsy specimens to be taken in similar cases.
- With regard to postulates related to the cause of endometriosis which was first described by Rokitansky in 1860, there is no consensus opinion but two postulates (a) the implantation of endometrial cells (implantation theory) promulgated by Sampson [60] and (b) the metaplasia of peritoneal epithelium (the coelomic metaplasia theory) favoured by Agarwal and Subramanian. [61] However, the two postulates individually do not explain fully all the cases of endometriosis encountered.
- It has been stated that perhaps the frequent occurrence of retrograde menstruation would be a strong point of argument that could be used in the support of the implantation theory [62].
- Nevertheless, some authors [63] [64] had stated that how these endometrial cells could reach atypical sites like the brain and the heart or in their case the parenchyma of the liver would be very difficult to



explain based upon the implantation theory. With regard to this some authors [7] [60] [65] have suggested that perhaps the transportation of endometrial cells through the blood stream and lymphatic channels, like in cases of metastasis of cancerous cells, could be a conjectural explanation for the atypical locations of the endometriosis lesions. Furthermore, Keichel et al. [65] did find endometriosis-like cells within the lymphatic channels and also endometriosis within the loco-regional lymph nodes of patients who had deep infiltrating endometriosis.

- It had also been suggested that perhaps, the metaplasia of peritoneal epithelium as a sequel of chronic inflammation of an unknown signalling cascade could be a better explanation for the development of endometriosis in obscure sites; such as within the heart, or even in a male.
- Despite the aforementioned theories relating to the cause of endometriosis a number of questions remain un-answered like why do the atypical endometriosis lesions occur only on one site in a patient?
- It has been recommended that in cases of endometriosis of the liver a selective operation must be considered a priority even if the possibility of malignancy is rare. [66]
- Life-long hormonal treatment might also lead to reduction of symptoms as reported by Inal et al. [33] in their case but this approach to treatment would carry the risk of side effects and long-term dependence on medication.

Adishesh et al. [67] in 2016 reported a 23-year-old woman who had been having cyclical abdominal and pelvic pain associated with menstruation of several years duration. She was nulliparous and had been having regular periods and had also been on contraceptive pill. She had been having constant shoulder tip pain. She had undergone laparoscopy which did reveal extensive endometriosis and some of the lesions were excised and she was referred onto another institution. She underwent another laparoscopy in the recipient hospital which revealed diffuse endometriosis in the pelvis that included the rectovaginal space and her uterosacral ligaments bilaterally. There was also endometriosis that involved her diaphragm and a separate area over her liver. An extensive excision of her endometriosis was undertaken; however, the area of endometriosis on the liver was not excised in view of the possibility of a high risk of bleeding and the fact that she had not been consented for excision of endometriosis involving the liver. Adishesh et al. [67] stated the following:

- Their review of the literature had revealed a total of 18 cases of endometriosis of the liver and out of these cases in twelve cases (67%) a previous history of endometriosis had been reported, mostly in a the typical pelvis position, but on the other hand in six cases (33%) did not have any history of endometriosis. Furthermore, six of the 18 cases of endometriosis of liver reported in the English literature were diagnosed in post-menopausal women which would indicate that endometriosis of the liver is not limited to women of the reproductive ages only. In view of difficulties in establishing the diagnosis of endometriosis pre-operatively by use of radiological imaging [32] [59], only 7 of the reported 18 cases of endometriosis of the liver had been diagnosed pre-operatively [59] In view of this it would appear that a significant gynaecological history may not be of help in the pre-operative diagnosis of endometriosis of the liver.

- In view of lack of specific features on radiological imaging that would be diagnostic of endometriosis of the liver, a definitive way to establish diagnosis of the disease would involve trans-hepatic biopsy of the liver lesion for histological examination. The biopsy procedure should be discussed with each patient and to explain the potential complications of the procedure including bleeding, possible dissemination of cells, biliary leakage as intimated by Fluegen et al. [59]

- Endometriosis of the liver had been managed by means of surgical excision, or ultrasonic aspirator. Nevertheless, as reported by Inal et al. [33] lifelong hormonal treatment may improve the symptoms of the disease but this would tend to be associated with the risk for side effects and the long-term dependence on medication.

- A question that needs to be addressed is whether or not endometriosis of the liver can be managed effectively by means of a non-operative hormonal treatment using danazol and gonadotrophin analogues like buserelin, goserelin, leuprorelin as sole treatment option or they could be used to prevent recurrence of the disease post-operatively. This question would need to be answered in view of the fact that so far there is only one reported case where Danazol was used as treatment when the patient refused to undergo surgery but this report lacks long-term follow-up data. [33]

Globally endometriosis is common but endometriosis of the liver is rare and its diagnosis would require a high index of suspicion. It is conjectural but it could be argued that the rarity of endometriosis of the liver may be because a large number of women are treated for menstruation

associated pain without thorough investigation including ultrasound scan of abdomen and pelvis and that perhaps if all women who have menstruation associated pain undergo ultrasound scan of abdomen and pelvis more cases of endometriosis of the liver and other extra-genital could be diagnosed which would allow for early treatment of curative intent to be given.

### Conclusions

Globally endometriosis of the liver is rare and this rarity could be partly due to under-diagnosis of the disease or perhaps genuinely the disease is rare. The only way to ensure that cases of extra-pelvic endometriosis including endometriosis are not missed is for clinicians to thoroughly investigate all patients with menstruation associated pain with inclusion of radiological scanning of abdomen and pelvis.

**Conflict of Interest:** None

**Acknowledgements:** Acknowledgements to:

[1] The European Journal of Medical Research for granting copy right permission for contents and figures from their Journals to be reproduced under the Creative Commons Attribution License provided the original source is cited.

[2] HPB Surgery: a world journal of hepatic, pancreatic and biliary surgery for granting copy right permission for contents and figures from their Journals to be reproduced under the Creative Commons Attribution License provided the original source is cited.

### References

1. Finkel L, Marchevsky A, Cohen B. Endometrial cyst of the liver. *Am. J. Gastroenterol* 1986 Jul; 81(7): 576 – 578
2. Gudice LC, Clinical practice, Endometriosis. *N Engl J Med* 2010; 362: 2389 - 2398
3. Haas D, Cnvater R, Reichert B, Renner S, Shebl O, Binder H, et al. Endometriosis: a premenopausal disease? Age pattern in 42079 patients with endometriosis *Arch Gynecol Obstet.* 2012; 286: 667 - 670
4. Markham SM, Carpenter SE, Rock JA. Extrapelvic endometriosis. *Obstet Gynecol Clin North Am* 1989; 16: 193 – 219
5. Liu K, Zhang W, Liu S, Dong B, Liu Y. Hepatic endometriosis: a rare case and review of the literature *European Journal of Medical Research* 2015; 20: 48 DOI: 10.1186/s40001-015-0137-1
6. Martin Jr D, Hauck A E. Endometriosis in the male *Am Surg* 1985; 51: 426 - 430

7. Goldsmith PJ, Ahmad N, Dasgupta D, Campbell J. GuthrieJ A, Lodge J P A. Case Hepatic Endometriosis: A Continuing Diagnostic Dilemma. *HPB Surgery: a world journal of hepatic, pancreatic and biliary surgery* Volume 2009; Article ID 407206, 4 pages doi: 10.1155/2009/407206
8. Sataloff DM, La Vorgna KA, McFarland MM. Extrapelvic endometriosis presenting as a hernia: clinical reports and review of the literature. *Surgery* 1989; 105(1): 109 – 112
9. Vinatier D, Orazi G, Cosson M, Dofour P. Theories of endometriosis. *Eur. J. Obstet Gynecol Reprod Biol.* 2001; 96: 21 – 34
10. Arruda MS, Petta CA, Abrão MS, Banetti-Pinto C L. Time elapsed from the onset of symptoms to diagnosis of endometriosis in a cohort study of Brazilian women. *Hum. Reprod* 2003; 18: 756 – 759
11. Podgac S, Gonçalves MO, Klajner S, Abrão M S. Epigastric pain relating to menses can be a symptom of bowel endometriosis. *São Paulo Med. J.* 2008; 126: 242 – 244
12. Beckman EN, Pintado SO, Leonard GL, Stemberg WH. Endometriosis of the prostate *Am J. Surg Pathol* 1985 May; 9(5): 374 – 379
13. Taguchi S, Enomoto Y. Bladder endometriosis developed after long-term oestrogen therapy for prostate cancer. *International Journal of Urology* 2012 Oct; 19(10): 964 – 965
14. Zámecnik M, Hostakova D. Endometriosis in a mesothelial cyst of tunica vaginalis of the testis. Report of a case. *Cesk Patol* 2013 Jun; 49(3): 134 – 136
15. Giannarini G, Scott CA, Moro U, Grossetti B, Pomara G, Selli C. Cystic endometriosis of the epididymis. *Urology* 2006 Jul; 68(1): 203: e1 – e3
16. Fukunaga M, Paratesticular endometriosis in a man with prolonged hormonal therapy for prostatic carcinoma. *Pathol Res Pract* 2012 Jan 15; 208(1): 59 – 61 DOI: 10.1016/j.prp.2011.10.007. Epub 2011 Nov 21
17. Pinkert TC, Catlow CE, Straus R. Endometriosis of the urinary bladder in a man with prostatic carcinoma. *Cancer* 1979 Apr; 43(4): 1562 – 1567

18. Jabr FI, Mani V. An unusual cause of abdominal pain in a male patient: Endometriosis. *Avicenna J Med* 2014; 4: 99 – 101
19. Simsek G, Bulus H, Tas A, Koklu S, Yilmaz S B, Coskun A. An Unusual Cause of Inguinal Hernia in a Male Patient: Endometriosis. *Gut Liver* 2012 Apr; 20(2): 284 – 285 DOI: 10.5009/gnl.2012.6.2.284
20. Viganò P, Parazzini F, Somigliana E, Vercellini P. Endometriosis: Epidemiology and aetiological factors. *Best Pract Res Clin Obstet Gynecol.* 2004; 18: 177 – 200
21. Vercellini P, Fedele L, Aimi G, Pietro Pietropaolo G, Consonni D, Crosignani P G. Association between endometriosis stage, lesion type, patient characteristics and severity of pelvic pain symptoms: a multivariate analysis of over 1000 patients. *Hum Reprod.* 2007; 22: 266 – 271
22. Bellelis P, Antônio Dias Jr. J, Podgaec S, Gonzales M, Baracat EC, Abrão MS. Epidemiological and clinical aspects of pelvic endometriosis – A case series. *Rev Assoc Med Bras* 2010; 56(4): 467 - 471
23. Bischoff FZ, Simpson JL. Heritability and molecular genetic studies of endometriosis *Human Reprod Update* 2000 Jan - Feb; 6(1): 37 – 44
24. Marchairiotis N, Aikaterini S, Dryllis G, Zarogoulidis P, Kouroutou P, Tsiamis N, Katsikogiannis N, Sarika E, Couroutsakis N, Tsiouda T, Gschwendtner A, Zarogoulidis K, Sakkas L, Baliaka A, Machairiotis C. Extrapelvic endometriosis: a rare entity or underdiagnosed condition? *Diagnostic Pathology* 2013; 8: 194 DOI: 10.1186/1746-1596-8-194
25. Simpson JL, Bischoff FZ, Kamat A, Buster JE, Carson SA. Genetics of endometriosis. *Obstet Gynecol Clin North Am.* 2003 Mar; 30(1): 21 – 24
26. Treloar SA, O'Connor DT, O'Connor VM, Martin N G. Genetic influences on endometriosis in an Australian twin sample. [suet@qimr.edu.au](mailto:suet@qimr.edu.au). *Fertil Steril* 1999 Apr; 71(4): 701 – 710
27. Johnson NP, Hummelshoj L. World Endometriosis Society of MontPellier Consortium. Consensus on current management of endometriosis *Hum Reprod* 2013 Jun; 28(6): 1552 – 1568 DOI: 10.1093/humrep/det050. Epub 2013 Mar 25
28. Khan AW, Craig M, Jamulowicz M, Davidson B R, Liver tumours due to endometriosis and endometrial stromal sarcoma *HPB (Oxford)* 2002; 4(1): 43 – 45 DOI: 10.1080/136518202753598735
29. Chang KL, Crabtree GS, Lim-Tan SK, Kempson RL, Hendrickson MR. Primary extrauterine endometrial stromal neoplasms: a clinicopathologic study of 20 cases and a review of the literature. *Int J. Gynecol Pathol.* 1993 Oct; 12(4): 282 – 296
30. Norris H, Taylor H. Mesenchymal tumours of the uterus: a clinical and pathological study of 53 endometrial stromal tumours. *Cancer* 1996 Jun, 19(6): 755 – 766
31. Huang W-T, Chen W-J, Chen C-L, Chang Y-F, Wang J-H, Eng H-L. Endometrial cyst of the liver: a case report and review of the literature. *Journal of Clinical Pathology* 2002; 55: 715 – 717 doi: 10.1136/jcp.55.9.715
32. Asran M, Rashid A, Szklaruk J. Hepatic Endometriosis Mimicking Metastatic Disease: A Case Report and Review of the literature. *Journal of Radiology Case Reports* 2010 Nov; 4(11): 26 – 31. DOI: 10.3941/jrcr.v4i11.589
33. Inal M, Bicackci K, Sovupak S. Hepatic endometrioma: a case report and review of the literature. *Eur Radiol* 2000; 10(3): 431 – 434
34. Theodosopoulos T, Viallourou A I, Hatzipappas J, Koutoulidis V, Dadniis N, Contis J. Right-Shoulder Pain: An Usual Sign of Hepatic Endometriosis *Journal of Gynecologic Surgery.* 2014 Dec; 30(6): 383 – 385. Doi: 10.1089/gyn.2014.0071.
35. Tuech J-J A, Rousselet M-C, Bover J, Descamps P, Arnaud J-P, Ronceray J. Endometrial cyst of the liver: case report and review. *Fertility and Sterility* 2003 May; 79(5): 1234 – 1236
36. Sabrina S C, Rosado F G N, Smith J J, Merchant N B, Chanjuan S. Hepatic uterus-like mass misdiagnosed as hepatic abscess. *International Journal of Surgical Pathology* 2015 Apr; 23(2): 134 – 139
37. Hertel J D, Guimaraes M, Yang J. Hepatic endometriosis diagnosed by liquid-based



- cytology: A Case Report. *Diagn Cytopathol* 2014; 42: 441 – 444 DOI: 10.1002/dc.22943
38. Rivkine E, Jakubowicz D, Marciano L, Polliang C, Zioli M, Banal C. Hepatic endometrioma: a case report and review of the literature: report of a case. *Surgery Today* 2013 Oct; 43(10): 1188 – 1193
  39. Kaikur S, Raza A, Richardson R E Right upper quadrant pain? Think outside the liver: a case of diaphragmatic perihepatic endometriosis. *The Journal of obstetrics and gynaecology* 2013 Oct; 33(7): 743 – 744
  40. Bouras A F, Vincentelli A, Boleslawski E, Truant S, Liddo G, Prat A, Pruvot F R, Zerbib P. Liver endometriosis presenting as a liver mass associated with high blood levels of tumoral biomarkers. *Clinics and research in hepatology and gastroenterology* 2013 May; 37(3): e85 -88
  41. Watari H, Shibahara N, Ebisawa S, Nogami T, Fujimoto M, Hikiami H, Shimada Y. Case report: A case of endometriosis with periodic right upper quadrant pain. *Nihon Naika Gakkai Zasshi. The Journal of the Japanese Society of Internal Medicine* 2012 Nov 1; 10(11): 3233 – 3235
  42. Roesch-Dieten F, Jiménez-García A, Pérez-Morales A, Grube-Pagola P, Ramirez-Cervantes K L, Remes-Troche J M. Hepatic endometriosis Images in Hepatology *Annals of Hepatology* 2011 Jul – Sep; 10(3): 347 – 348
  43. Schuld J, Justinger C, Wagner M, Bohle R M, Kollmar O, Schilling M K, Richter S. Bronchobiliary fistula: a rare complication of hepatic endometriosis. *Fertility and Sterility* 2011 Feb; 95(2): 804. E15
  44. Sanchez-Perez Belinda, Santoyo-Santoyo J, Suarez-Munoz M A, Fernandez-Aguilar J L, Aranda-Navaez J M, Gonzalez-Sanchez A, De La Fuente-Peruchio A. Hepatic cystic endometriosis with malignant transformation. *Chirurgia española* 2006 May; 79(5): 310 – 312
  45. Nezhat C, Kazerooni T, Barker B, Lashey N, Fernandez S, Marziali M. Laparoscopic management of hepatic endometriosis: report of two cases and review of the literature. *Journal of minimally invasive gynaecology* 2005 May; 12(3): 196 – 200
  46. Gerianda R, Howard E R, Heaton N D. Perihepatic endometriosis. *International Journal of Gynaecology and Obstetrics: the official organ of the international federation of gynaecology and obstetrics* 2005 Mar; 88(3): 338 – 339
  47. Reid G D, Knowles D, Cooper M J W, Kelco P. Hepatic endometriosis: a case report and review of the literature. *The Australian & New Zealand Journal of Obstetrics and Gynaecology* 2003 Feb; 43(1): 87 – 89
  48. Jeanes A O, Murray D, Davidson B, Hamilton M, Watkinson A F. Case report: hepatic and retroperitoneal endometriosis presenting as obstructive jaundice with ascites: a case report and review of the literature. *Clinical radiology* 2002 Mar; 57(3): 228 – 229
  49. Groves AM, Whitfield R, Lomas DJ, Gibbs P. Imaging of a hepatic endometrioma in a patient with multiple haemangiomas. *J Hepatol* 2003 Apr; 38(4): 547 DOI: 10.1016/S0168-8278(03)00019-9
  50. N'senda P, Wendum D, Ballardur P, Dahan H, Tubiana J M, Arrive L. Adenosarcoma arising in hepatic endometriosis. *European radiology* 2000; 10(8): 1287 – 1289
  51. Chung CC, Liew CT, Hewitt PM, Leung KL, Lau WY. Endometriosis of liver. *Surgery* 1998 Jan; 123(1): 106 – 108
  52. Cravello L, D'arcole C, La Treut Y P, Blanc B. Hepatic endometriosis: a case report. *Fertility and sterility* 1996 Oct; 66(4): 657 – 659
  53. Verbeke C, Haris M, Stunn J. Cystic endometriosis of the upper abdominal organs. Report of three cases and review of the literature *Pathology, research and practice* 1996 Mar; 192(3): 300 – 304 discussion 305
  54. Nakanishi K, Bohndorf K, Lindemann F, Leipprand E. Endometriosis of the liver: findings of imaging diagnosis. *Rofo: Fortschntte auf dem Gebiele dei Rontgenstrahlen und der Nuklearmedizin* 1984 Oct; 161(4): 379 – 381
  55. Losa Garcia JE, Sanchez Sanchez R, Garcia Iglesias MC, Gonzalez Villaron L. Endometriosis with urinary involvement associated with hepatic hemangioma *Medicina clinica* 1993 Feb 27; 100(8): 318

56. Grabb A, Carr I, Goodman JD, Mendelson DS, Cohen B, Finkel L. Hepatic endometrioma J Clin Ultrasound. 1986; 14: 478 – 480 DOI: 10.1002/jcu.1870140616
57. Rovati V, Faleschini E, Vercellini P, Nervetti G, Tagliabue G, Benzi G. Endometrioma of the liver. Am. J Obstet Gynecol 1990; 163: 1490 – 1492 DOI: 10.1016/0002-9378(90)90611-A.
58. Weinfeld R M, Johnson S C, Lucas C E, Saksouk F A. CT diagnosis of perihepatic endometriosis complicated by malignant transformation. Abd Imaging. 1998; 23: 183 – 184 DOI: 10.1007/s002619900317.
59. Fluegen G, Jankowaik F, oehrding L Z, Kroepil F, Knoefel W T, Topp S A. Intrahepatic endometriosis as differential diagnosis: Case report and literature review. World Journal of Gastroenterology 2013 Aug; 7: 19(29): 4818 – 4822
60. Sampson J A. metastatic or Embolic Endometriosis, due to the Menstrual Dissemination of Endometrial Tissue into the Venous Circulation. Am J Pathol 1927; 3: 93 – 110 43[PMID: 19969738
61. Agarwal N, Subramanian A. Endometriosis – morphology, clinical presentations and molecular pathology. J Lab Physicians 2010; 2: 1 – 9 [PMID: 21814398
62. Liu DT, Hitchcock A. Endometriosis: its association with retrograde menstruation, dysmenorrhoea and tubal pathology. Br J Obstet Gyneacol 1986; 93: 859 – 862 [PMID: 3741813
63. Ceccaroni M, Clarizia R, Placci A. Pericardial, pleural, and diaphragmatic endometriosis. J Thorac Cardiovasc Surg 2010; 140: 1189 – 1190 [PMID: 20951262
64. Ichida M, Gomi A, Hiranouchi N, Fujimoto K, Suzuki K, Yoshida M, Nokubi M, Masuzawa T. A case of cerebral endometriosis causing catamenial epilepsy Neurology 1993; 43: 2708 – 2709 [PMID: 8255485
65. Keichel S, Bacteria de Arellano ML, Reichelt U, Riedlinger WF, Schneider A, Köhler C, Mechsner S. Lymphangiogenesis in deep infiltrating endometriosis. Hum Reprod 2011; 26: 2713 – 2720 [PMMID: 21791438
66. Jelovsek JE, Winans C, Brainard J, Falcone T. Endometriosis of the liver containing mullerian adenocarcinoma: case report. Am J Obstet Gynecol 2004; 191: 1725 – 1727 [PMID: 15547552
67. Adishesh A, Hawarden A, Rowlands D. Endometriosis of the liver. British Journal of Hospital Medicine 2016 May 11; 77(5): 310 – 311. DOI: <http://dx.doi.org/10.12968.77.5.310>

**Table 1:** A list of reported cases endometriosis of the liver reported with miscellaneous summary of data on the cases

Reference and year of report	Age in years	Site of liver involved Indication	History of endometriosis	Pre-operative diagnosis	Treatment	Outcome
Finkel et al. [1] 1986	21	Left lobe – Right upper quadrant pain	No previous removal of fallopian tube cyst – details not available to author	No	Enucleation of cyst	Follow-up details not available to author
Grabb et al. [56] 1986	21	Left lobe	No	No	De-roofing and danazol	Follow-up details not available to

					medication	author
Rovati et al. 1990 [57]	37	Left lobe Right upper quadrant pain & mass	Yes	Yes	Segmental resection of liver & Danazol medication	Details not available
Verbeke et al. [53] 1996	62	Left lobe	No	No	Excision of liver lesion	Details not available
Verbeke et al. [53] 1996	34	Right lobe	No	No	Right hepatectomy	Details not available
Cravello et al. [52] 1996	34	R subcostal pain cyclical pain Right lobe	Yes – history but no previous endometriosis treatment		Gonadotrophin releasing hormone agonist; (GnRH-a) Metastasectomy	GnRH-a therapy for 4 months led to clinical and radiological improvement & surgery performed to allow pregnancy
Weinfeld et al. [58] 1998	60	Right lobe	Yes	No	Left hepatectomy + excision	Details not available
Inal et al. [33] 2000	25	Right lobe	Yes	No	Danazol	Details not available
N'senda et al. [50] 2000	54	Right lobe	No	Yes	Right hepatectomy	Asymptomatic & no recurrence at 2 years follow-up
Huang et al. [31] 2002	56	Left lobe	Yes	No	Left hepatectomy	No follow-up details in case report
Jeanes et al. [48] 2002	31	Both lobes of liver	Yes	Yes	Right hepatectomy	Details not available
Khan et al. [28] 2002	31	Both lobes of liver	Yes	Yes	Right hepatectomy plus goserelin	Asymptomatic 4 years later
Khan et al. [28] 2002	61	Right lobe	Yes	Yes	Right hepatectomy histology endometrial stromal sarcoma (ESS)	Asymptomatic for 4 years with no recurrence
Tuech et al. [35] 2003	42	Right lobe	No	No	Excision of liver lesion	Asymptomatic & no recurrence at 22 months follow-up
Reid et al. [47] 2003	46	Right lobe	Yes	No	Right hepatectomy and goserelin	Details not available



						available
Groves et al. [49] 2003	52	Right lobe	No	No	Right hepatectomy	Details not available
Goldsmith et al. [7] 2009	48	Left lobe	Yes	No	Non anatomical resection of the liver lesion	Asymptomatic & no recurrence after 7 years
Sanchez Perez, et al. [44] [2006]	Age not available to author	Right lobe	Details unknown	Details not available to author	Right hepatectomy Histology showed in situ adenocarcinoma in endometrioma	Follow-up details not available
Asran et al. [32] 2010	61	Both lobes of liver	Yes	Yes	Mode of treatment not available to author only CT- guided trucut biopsy of liver lesion	Follow-up details not available
Schuld et al. [43] 2011	39	Right lobe of liver plus bronchopulmonary fistula	No	No	Segmental resection of Right lobe of liver & excision of bronchopulmonary fistula via laparotomy and thoraco-abdominal incision	Long-term follow-up details after synchronous liver and lung resection for bronchopulmonary fistula not available
Roesch-Dieten et al. [42] 2011	25 years	Surface of liver and right parietal peritoneum	No	No	She had laparoscopic cholecystectomy for gall stones plus biopsy of lesions on surface of liver and right parietal peritoneum which showed endometriosis which was treated post operatively with Danazol	She was discharged 2 days later. At follow-up she was asymptomatic but follow-up time not stated
Watari et al. [41] 2012	Age not available to author	Details not available (article in Japanese)	Details not available	Details not available	Details not available	Details not available
Fluegen et al. [59] 2013	32	Right lobe	No	No	Pericystectomy	Patient was discharged on 11 <sup>th</sup> post-operative day no follow-up data

Rivkine et al. [38] 2013	51	Left lobe	No	No	Left hepatectomy anatomical resection with left lobectomy of liver plus resection of diaphragm	No long-term follow-up information available
Bouras et al. [40] 2013	35	Left lobe of liver, atrium and diaphragm	No	No	Left hepatectomy plus excision of atrial wall and diaphragm	Alive & well at 5-year follow-up no recurrence 26
Hertel et al. [37] 2014	44	Right lobe	No	Cyst but type of cyst unknown	Aspiration of cyst	Details of long-term follow-up unknown 27
Theodosopoulos et al. [34] 2014	38	Right lobe & diaphragm	Yes		Wedge excision of liver lesion and right diaphragm lesion	Alive & well with no recurrence at 6-month follow-up 28
Liu et al. [62] 2015	36	Left lobe (segment III)	No	No	Pericystectomy	At 3 months follow-up patient was asymptomatic with no recurrence
Sabrina et al. [36] 2015	47	Lobe not available	No	No	Laparoscopic excision of cyst	Asymptomatic & no recurrence at time of report, long-term report not available
Adishesh et al. [67] 2016	23 years	Site not stated	Yes of pelvis at first laparoscopy	No diagnosis confirmed at 2 <sup>nd</sup> laparoscopy	Excision of endometriosis in abdomen and pelvis but liver lesion left alone	Alive no long term outcome reported

**Table 2:** Age-group distribution of 28 patients with endometriosis where age was available out of the 30 reported cases of endometriosis of the liver

Age groups	Number of reported cases (patients)
0 to 20 years	0
21 to 30 years	5
31 to 40 years	10
41 to 50 years	5
51 to 60 years	5
61 to 70 years	3
Older than 70 years	0
Total	28