

Successful pregnancy in the shortest achondroplastic dwarf – a rare case report

Dr Kaliki Hymavathi*¹

1. Professor, Department of OBG, Narayana Medical College & Hospital, Nellore-524002, India

Abstract

Achondroplasia, the commonest cause of short-limbed dwarfism and also is the most common type of disproportionate short stature. It is a rare genetic disorder incidence being 1 in 15,000 to 1 in 40,000 live births. It is inherited as an autosomal dominant trait but most cases (80%) are due to mutations in the fibroblast growth factor receptor-3 (*FGFR-3*) gene located on 4p. Ninety-eight percent of cases of achondroplasia are caused by, a point mutation causing the substitution of Arginine for Glycine (G380R) in the transmembrane domain of the *FGFR-3* gene. The majority of cases is sporadic and results from a *de novo* paternal mutation. We report an interesting case of pregnancy in the shortest-108cm (so far reported) achondroplastic dwarf with successful maternal and perinatal outcome. During the course of her pregnancy the two main problems encountered were late onset asymmetric intrauterine growth restriction (IUGR) at 30 wks gestation and pregnancy induced hypertension at 32wks gestation. A caesarean section was performed under spinal anaesthesia at 33wks4d gestation, the prime indications being Short achondroplastic primi with contracted pelvis, severe oligohydramnios (AFI-4) and IUGR. A live female baby of wt.1.8 kgs with Apgar score of 8 was delivered. Detailed clinical examination of the neonate performed by the neonatologist revealed no obvious external congenital anomalies. Infantogram after 6 wks of birth revealed normal study. Baby is under close follow up still. To conclude, cases of achondroplasia are rarely seen. It is very rare to come across such a case with pregnancy and successful feto-maternal outcome. Last but not the least there the pressing need for adequate counseling of the couple and relatives in the pre pregnancy as well as during the antenatal period.

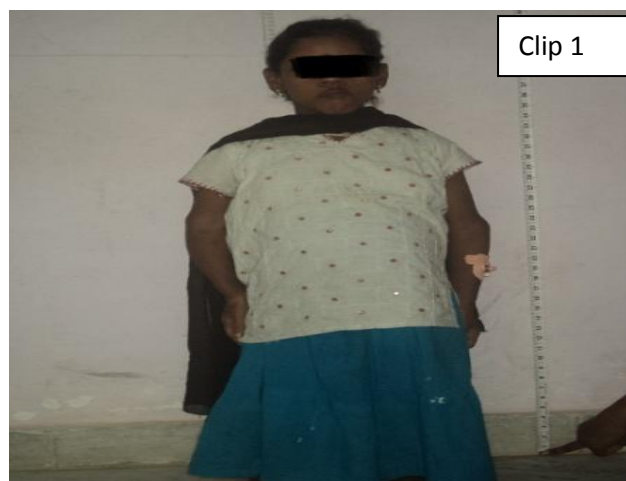Keywords: Achondroplasia-Pregnancy

*Corresponding Author: Dr. Kaliki Hymavathi, Professor, Dept. of OBG, Narayana Medical College, Nellore, Andhra Pradesh, India. E.mail: drhymakreddy@yahoo.co.in

Received: December 20, 2012 Accepted: January 10, 2012. Published: January 20, 2013. This is an open-access article distributed under the terms of the Creative Commons Attribution License, which permits unrestricted use, distribution, and reproduction in any medium, provided the original author and source are credited.

Introduction

Achondroplasia, the commonest cause of short-limbed dwarfism, is a rare genetic disorder inherited as an autosomal dominant trait. Incidence being 1 in 15,000 to 1 in 40,000 live births. We report an interesting case of pregnancy in the shortest-108cm (so far reported) achondroplastic dwarf (clip1) with successful maternal and perinatal outcome.



Case Report: Mrs. X, a short lady aged 25 yrs, married since 1 yr. attended at OBG department out patient with c/o 2 months amenorrhoea and with history of previous irregular menstrual cycles. She is a housewife, belonging to low socio economic status. On clinical examination, she is a disproportionate

dwarf with a height-108cm, Wt.35kgs and BMI-30. Head is larger than the body. Crowded teeth with poor alignment present. Thyroid & Breasts-Clinically normal. Spine- kyphosis and lordosis present with waddling gait. Bowing of legs and arms present. She has normal intelligence. General Examination - normal but for anemia. Abdominal examination - nil relevant. Local examination revealed normal external genitalia.

In view of her h/o irregular cycles with amenorrhoea of 2 months, a pregnancy test is asked for. The report has come as “**positive**”. Ultrasonogram (USG) revealed intra uterine pregnancy, a single fetus with cardiac activity. gestational age (GA) 7wks+/-2days. With the provisional diagnosis of pregnancy with achondroplasia, the husband is called for counseling. Her husband is of normal height and stature (150cm ht.) It was revealed by him that their's is III degree consanguinous marriage. No family history of dwarfism. Following counseling, since the couple has decided to continue the pregnancy, she is registered (Antenatal booking) and further evaluated.

Routine antenatal and specific investigations including thyroid profile, OGTT were done and found to be normal except for her Hb.% - 9gm/dl. USG for nuchal translucency and first trimester screening performed at 12 wks GA. The results were within normal range. As the couple denied for genetic evaluation of fetus, invasive procedures not performed. During 2nd trimester, triple screening, TIFFA scan and fetal ECHO were done and found to be normal. She was followed up carefully with regular antenatal checkups. Anemia treated with oral Iron (BD dose) and Folic acid. She was given 2 doses of TT. Till 30wks. of gestation the pregnancy was uneventful. At 30wks on clinical examination symphysio-fundal height was found to be only 27 cm, Obstetric USG performed. Which revealed asymmetrical intrauterine growth restriction (IUGR) with 2wks. disparity, Amniotic fluid index (AFI)-10 & Placenta- grade I maturity. Doppler study-Normal. Advised adequate rest, daily fetal movement count and alternate day amino infusions. Doppler study repeated after one week-normal study. At 32 wks. her blood pressure (BP) was 150/100 mm of Hg. She was admitted and evaluated further for Pregnancy induced hypertension (PIH). All the parameters were found to be normal. She was started on Tab. Methyl Dopa 500 mg BD. Repeat USG showed a disparity of 2 wks, with decreased fetal growth velocity. AFI-8. Doppler Study-Absent diastolic flow in Umbilical artery (UA) and normal pulsatility index (PI) in

Middle Cerebral artery (MCA). NST's performed thrice weekly with reassuring pattern. Amino infusions continued. Two doses of steroids were administered for enhancing fetal lung maturity.

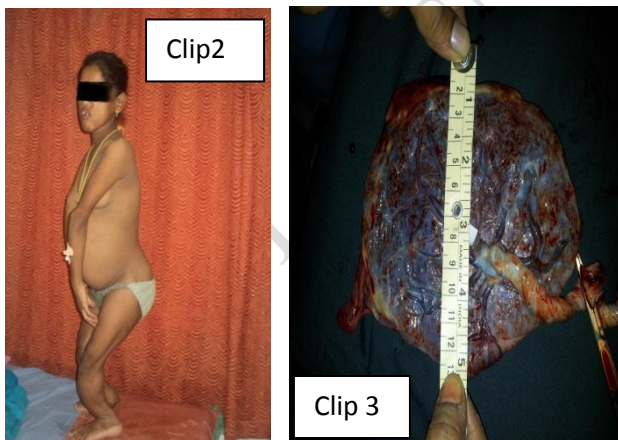
At 33 wks, of gestation, BP was found to be under control. Repeat PIH profile satisfactory. USG showed asymmetrical IUGR & oligohydramnios (AFI-6) with placenta- grade II maturity, estimated fetal weight-1.6kg. Doppler studies revealed absent diastolic flow in the U.A. with decreased PI in MCA. Kick charts normal. Daily NST-reassuring. Amino infusions on alternate days continued. Repeat USG after 4 days revealed AFI-4. In view of markedly reduced amniotic fluid index in a short span of time and gestational age (GA 33wks+4days) being satisfactory, decided for termination of pregnancy. Pelvic examination revealed unfavourable cervix with high presenting part (cephalic) and grossly contracted pelvis. Caesarean Section performed under Spinal anaesthesia, the prime indications being short achondroplastic primi with contracted pelvis, severe oligohydramnios and IUGR. A live female baby of wt.1.8 kgs with Apgar score of 8 was delivered. Detailed clinical examination of the neonate performed by the neonatologist. No obvious external congenital anomalies were noticed. Post operative period was uneventful & she got discharged after 1 week. Mother and baby were doing well at the time of discharge.

Discussion

A typical defining characteristic of dwarfism is an adult height of less than 147 cm (4 ft 10 in). Achondroplasia is a Greek word meaning "without cartilage formation" is one of the most common causes of dwarfism and also is the most common type of disproportionate short stature. It is a genetic disorder inherited as an autosomal dominant trait but most cases (80%) are due to mutations in the fibroblast growth factor receptor-three (*FGFR-3*) gene located on 4p¹. More than 95% of patients have the same point mutation in the gene for *FGFR3* and more than 80% of these are new mutations. The mutation which causes gain of *FGFR3* function affects many tissues most strikingly the cartilaginous growth plate in the growing skeleton leading to a variety of manifestations and complications. Ninety-eight percent of cases of Achondroplasia are caused by a point mutation causing the substitution of Arginine for Glycine (G380R) in the transmembrane domain of the *FGFR-3* gene although other disease-causing mutations have also been reported. It has

been observed that fathers above 40 years of age are more likely to have children with achondroplasia. The parents of children with achondroplasia resulting from a new mutation are usually of normal stature. Their chance of having a second affected child is extremely small. In our case since her parents are found to be of normal stature with no obvious skeletal abnormalities and as there is no other affected family member the occurrence of achondroplasia in this woman can be attributed to mutation rather than to autosomal dominant inheritance.

Clinical features of achondroplasia being normal trunk, short arms and short legs. There is proximal shortening of the limbs (rhizomelic dwarfism). The average adult height is 4 feet. The head appears larger than the body, with a prominent forehead and flattened bridge of the nose. Teeth may be crowded with poor alignment. Spine is usually straight in the upper back with a marked lumbar lordosis. Abnormalities of the thoraco lumbar vertebra may lead to kyphosis in infancy, which disappears once the child starts walking, but may cause spinal cord compression (lumbar spinal stenosis). There may be bowing of the legs and feet are generally short and flat. Hands are short with stubby fingers and there may be a trident hand (separation between the middle and ring fingers)¹ In our case this pregnant woman is found to have many of the above mentioned features typical of Achondroplasia.(clip2).



These individuals have normal mental and sexual development, and life span may be normal. In the present situation this woman's mental condition, sexual development including reproductive capacity all appear to be within normal limits.

Certain gynaecological problems like infertility, menorrhagia, dysmenorrhoea, leiomyomata and early menopause are more common in these patients¹. In the present case her age at menarche was 13 years her menstrual cycles were regular in the beginning and became oligomenorrhoeic afterwards. There is no history of infertility and she conceived spontaneously one year after marriage. In our case late onset IUGR noticed at 30wks gestation and pregnancy induced hypertension at 32wks gestation. Both could be managed to a satisfactory extent and pregnancy could be prolonged almost up to 34wks.

Antenatal detection of fetal Achondroplasia: The diagnosis may be suspected by ultrasound on the basis of disproportionately short limbs in the fetus. Prenatal sonographic diagnosis often fails as limb length is preserved until around 22 weeks gestation, after the time of the routine fetal anomaly scan. Presentation of *de novo* cases often occur in the third trimester when the fetus is scanned for some other reason and short limbs and other features such as trident hand and frontal bossing may be evident. Other features such as a small chest and bowing of the femora have only occasionally been reported. Definitive diagnosis can only be made by detecting the mutation in the *FGFR-3* gene or by postnatal radiology. The question of genetic testing in utero is a controversial subject and should be up to each family or individual. Genetic testing can be done if both the parents have achondroplasia. However, the identification of cell-free fetal DNA circulating in maternal blood offers an alternative approach to definitive prenatal diagnosis and has now been reported in several cases. Currently non-invasive prenatal diagnosis (NIPD) for single-gene disorders is limited to the detection or exclusion of alleles present in the fetus because they are inherited from the father or have arisen *de novo*. However, as the proportion of cell-free fetal DNA increases with gestation molecular diagnosis using cell-free fetal DNA when ultrasound features are suggestive of achondroplasia seems an ideal application for NIPD in view of the third-trimester presentation and hence increased concentrations of cell-free fetal DNA^{2,3}. Fetuses with homozygosity/ double dominant dwarfism are invariably either stillborn or die shortly after birth. Such pregnancies should be followed by ultrasound at 14, 16, 18, 22 and 32 weeks of gestation looking for fetal normalcy and growth pattern. In our case the fetal normalcy could be followed only by USS and serum markers but no invasive genetic studies could be done due to the couple's refusal. With regard to the fetal growth pattern in our case it

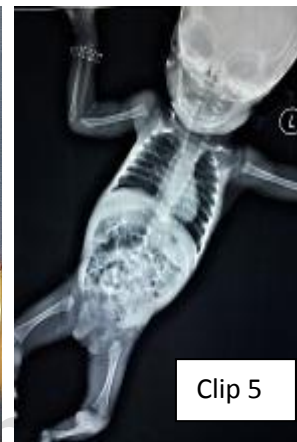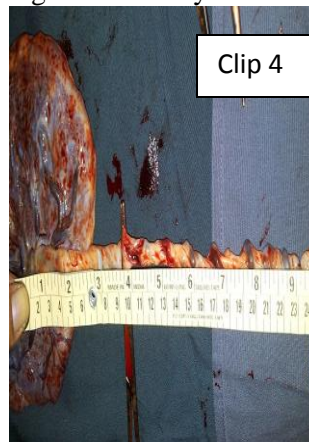
was normal till 30wks gestation when IUGR is suspected on clinical examination and confirmed by ultrasonogram. Since then she was followed up with periodic USS and Doppler studies for the fetal status assessment.

An expectant Achondroplastic mother invariably has to have delivery by Cesarean section due to existing abnormalities. Limited neck extension, foramen magnum stenosis, a large tongue, large mandible, and atlanto-axial instability can lead to increased difficulty of airway management. Severe kyphosis, scoliosis, spinal stenosis, and unpredictable spread of local anesthetics in the epidural space and subarachnoid space lead to reluctance to apply regional anesthesia in this patient group. In addition, pregnancy in a person with Achondroplasia poses more problems for anesthetic selection. These problems include potential hypoxia, severely decreased functional residual capacity, risk of gastric aspiration, and supine hypotension. Such a patient is considered high risk in terms of anaesthesia and obstetric outcome and there is enough room for prenatal counseling^{4,5,6,7}. There are risks for both regional and general anesthesia in achondroplastic patients. A baseline pulmonary function study should also be done as the mother may develop respiratory compromise in the third trimester of pregnancy and even during anaesthesia. The most important point is the careful preoperative assessment. Anesthesia plan should be specified to individual basis. In our case spinal anaesthesia could be given without much difficulty.

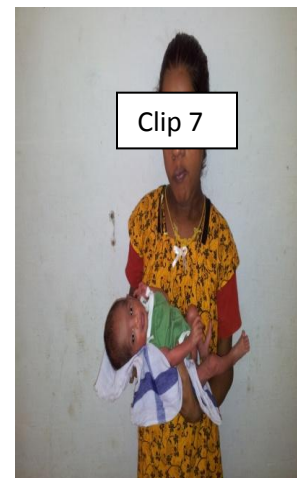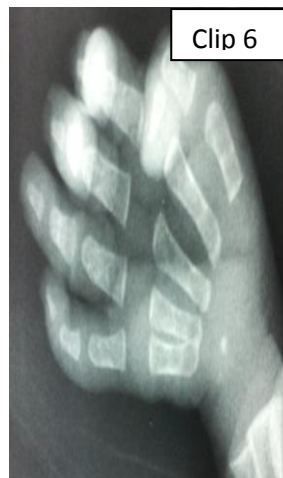Intra operative findings in our case: The lower uterine segment was found to be not well formed. The uterine incision had to be extended on both sides upwards (“smile” extension) to deliver the baby’s head. though the birth weight was only 1.8Kgs. This makes obvious a very narrow lower uterine segment which can be attributed to disproportionate dwarfism. Placenta was also found to be very small (dia.11cms) and almost 80% of the maternal surface was found to be studded with calcifications and infarcts (Placental insufficiency) and the Umbilical cord length was also very short-23cms (clip3&4).

Following delivery of placenta the size of the contracted Uterus was also found to be unusually small. There were no other problems intra operatively. Postoperative period was uneventful. With regard to neonatal, there may be increased

neonatal mortality due to hydrocephalus and thoracic cage abnormality.



In the newborn, the condition can be diagnosed by radiographic studies. Special achondroplasia growth curves and infant development charts are available from which expected adult height could be estimated. Serial arm span, head circumference, total body length and upper to lower body segment ratio should be evaluated in our case the baby was handed over to the neonatologist soon after delivery and clinical examination revealed normal appearance with no obvious anomalies. Infantogram done six weeks after birth revealed normal study (clip 5&6).



Since, hydrocephalus may develop during in the first two years, head circumference should be monitored monthly for the first year and every 3 monthly in the second year. Periodic monitoring of the baby becomes mandatory for early detection of anticipated problems and to plan the treatment protocols accordingly¹. The detailed pediatric follow-up protocol is beyond the scope of this article.

Last but not the least there is pressing need for adequate counseling of the couple and relatives.

All their questions and their doubts have to be patiently dealt with by the attending clinician and as well as the geneticist. In the pre pregnancy counseling the couple should be made aware of the existing problem and the probable chances of the children getting affected. It is also very important to stress on the fact that fetal disability is not always through genetic transmission from the affected parent but in majority of cases due to some unexplained errors the so called “mutations” that occur during embryogenesis. Parents who are achondroplastic due to gene mutations have a low risk of having another child with achondroplasia. An individual with achondroplasia who has a reproductive partner with average stature has a 50% risk in each pregnancy of having a child with achondroplasia. When both parents have achondroplasia, the chance to their offspring of having average stature is 25%; of having achondroplasia-50%; and of having homozygous achondroplasia (a lethal condition), 25%⁸. Prenatal testing for pregnancies at increased risk is possible. In the prenatal counseling the most frequently asked question by the parent is whether the baby is already affected or not. In case the fetal involvement is already evident by the mentioned means the option is up to the parents for the continuation/termination of pregnancy.

Future

The biology of FGFR3 and the molecular and cellular consequences of the Achondroplasia mutation are being elucidated, providing a more complete understanding of the disorder and a basis for future treatments targeted directly at relevant pathogenetic pathways. Furthermore, the natural history of the condition which has been well delineated in childhood and adolescence, is being defined more fully in adults with Achondroplasia⁹. There is growing evidence that mutations of FGFR3 confer a "gain of function". It is proposed that the normal function of FGFR3 is to slow down the formation of bone by inhibiting the proliferation of chondrocytes, the cells that produce cartilage. The mutation increases the activity of FGFR3, severely limiting bone growth. This theory is supported by the knock-out mouse model in which the receptor is absent, and so the negative regulation of bone formation is lost. The result is a mouse with excessively long bones and elongated vertebrae, resulting in a long tail. Achondroplastic mouse models are useful tools in developing potential treatments.¹⁰ Most of the serious complications can be modified favorably or prevented by anticipation and early treatment. Possible future treatments include chemical inhibition

of receptor signalling, antibody blockade of receptor activation, and alteration of pathways that modulate the downstream propagation of FGFR3 signals. With regard to fetal diagnosis in utero-Improving the accuracy of the sonographic diagnosis of this condition will facilitate targeted molecular diagnosis, which can now be done safely using cell-free fetal DNA extracted from maternal plasma, to confirm the diagnosis and also for improved parental counseling.

References

1. Ghumman S, Goel N, Rajaram S, Singh K.C, Kansal B, Dewan P. Pregnancy in an achondroplastic dwarf. *Jour of the Indian medical association*. 2005;103(10):536-538.
2. Lim JH, Kim MJ, Kim SY, Kim HO, Song MJ, Kim MH, Park SY, Yang JH, Ryu HM. Non-invasive prenatal detection of achondroplasia using circulating fetal DNA in maternal plasma. *J Assist Reprod Genet*. 2011;28(2):167-172.
3. Chitty LS, Griffin DR, Meaney C, Barrett A, Khalil A, Pajkric G, Cole TJ. New aids for the noninvasive prenatal diagnosis of achondroplasia: dysmorphic features, charts of fetal size and molecular confirmation using cell-free fetal DNA in maternal plasma. *Ultrasound Obst Gynaecol*. 2011;37(3):283-289.
4. Mikhael, Hosni, Vadivelu, Nalini, Braveman, Ferne Safety of Spinal Anesthesia in a Patient with achondroplasia for Cesarean Section. *Current drug safety*. 2011;6(2):130-131.
5. Cevik B, Colakoglu S. Anaesthetic management of achondroplastic dwarf undergoing caesarean section. *Middleeast J. Anaesthesiol*. 2010;20(6):907-910.
6. Huang J, Babins N. Anaesthesia for caesarean delivery in an achondroplastic dwarf - a case report. *AANA J*. 2008;76(6):435-436.
7. M J Morrow, I H Black. Epidural anaesthesia for caesarean section in an achondroplastic dwarf *Br. J. Anaesth*. 1998;81(4):619-621.
8. Richard M Pauli. Achondroplasia. Gene reviews; BookshelfID:NBK1152 PMID: 2030133 1: Last update February 16, 2012.
9. William A Horton, Judith G Hall, Jaqueline T Hech. Achondroplasia. *The Lancet* 14-20 July 2007;370(9582):162-172.
10. Achondroplasia-Genes and Disease. Bookshelf ID: NBK22217